

A linear sigmoid colon passage method by left twisting

Satoshi Awazu, Risa Araki, Toshihiko Awazu

Awazu Hospital, Nagasaki, Japan

Address correspondence to Satoshi Awazu, Awazu Hospital, Nagasaki 851-0251, Japan. Phone: +81-95-826-9088. E-mail: planeaaaaa@yahoo.co.jp.

ABSTRACT

We previously reported that the sigmoid-descending colon junction becomes linear and the colonoscope can be readily inserted into the descending colon in the left semiprone position. In addition, we encountered a situation whereby the sigmoid colon becomes more linear and the colonoscope can be more straightly inserted in the sigmoid colon when the colonoscope is inserted with twisting to the left in the left semiprone position. Therefore, our new insertion method was devised so that the colonoscope neutral position was rotated 45 degrees to the left compared to our conventional insertion method, and this method was performed to determine whether the colonoscope looping rate in the sigmoid colon can be reduced. The colonoscope looping rate in the sigmoid colon could be reduced by using our new insertion method. These results suggest that safer colonoscope insertion is possible by using our new insertion method compared with our conventional insertion method.

INTRODUCTION

Colonoscopy looping in the sigmoid colon is considered to cause intestinal perforation (Lüning et al., 2007; Magdeburg et al., 2008; Shah et al., 2000).

We previously reported that the sigmoid-descending colon junction becomes linear and the colonoscope can be readily inserted into the descending colon in the left semiprone position (Awazu, Araki & Awazu, 2012). Therefore, we considered that the sigmoid colon also becomes linear and the colonoscope can be readily inserted in the sigmoid colon in the left semiprone position.

In addition, we encountered a situation whereby the sigmoid colon becomes more linear and the colonoscope can be more straightly inserted in the sigmoid colon when the colonoscope is inserted with twisting to the left in the left semiprone position (Fig. 1). Therefore, we considered that the colonoscope can be more readily inserted in the sigmoid colon when the colonoscope is inserted with twisting to the left in the left semiprone position.

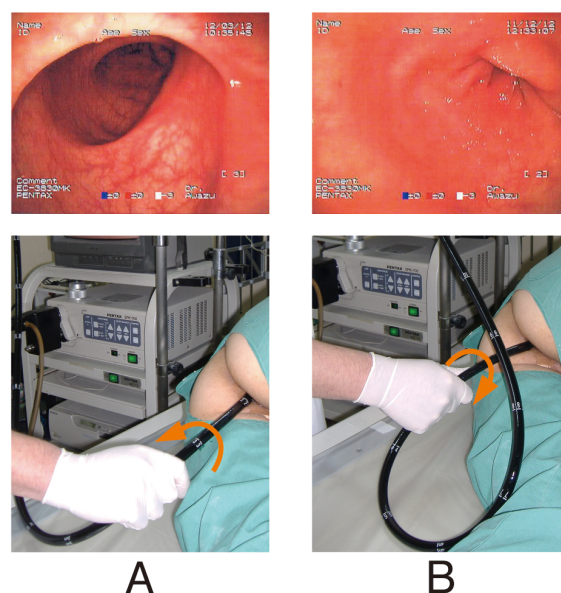


Figure 1. The situation we encountered. The patient was placed in the left semiprone position. The colonoscope tip was present in the rectosigmoid colon. When the colonoscope was twisted to the left, the lumen of the sigmoid colon was observed linearly in the left direction (A) and the colonoscope could be straightly inserted. By contrast, when the colonoscope was twisted to the right, the lumen of the sigmoid colon was observed crookedly in the right direction (B) and the colonoscope was inserted with bending.

MATERIALS & METHODS

The Pentax EC-3830MK (HOYA, Akishima, Tokyo) was used. Our new insertion method was devised (Fig. 2) so that the colonoscope neutral position was maintained as shown in Fig. 1-A.

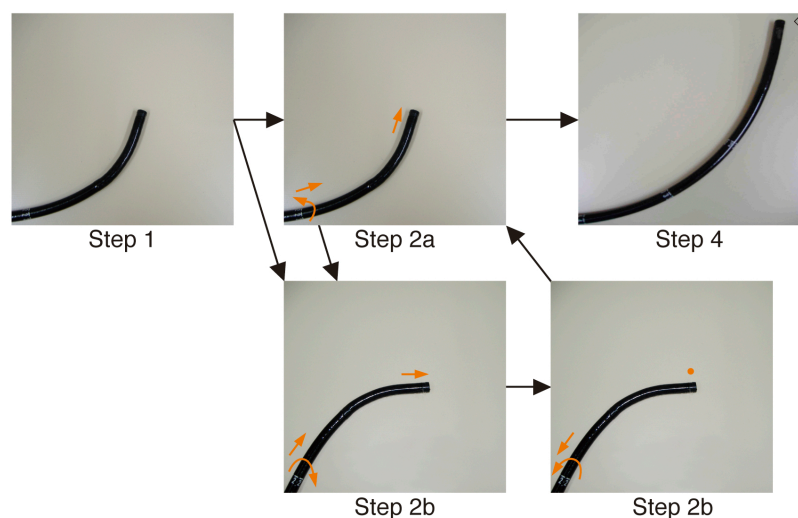


Figure 2. Our new insertion method. The shape of the colonoscope and movements of its tip are observed by

using fluoroscopy. Step 1. The colonoscope tip is present in the rectosigmoid colon. The patient is placed in the left semiprone position, and the colonoscope neutral position is determined as shown in Fig. 1-A. Step 2a. When the lumen of the sigmoid colon is observed in the left direction, the colonoscope is pushed with twisting to the left, which results in colonoscope advancement. Step 2b. When the lumen of the sigmoid colon is observed in the right direction, the colonoscope is pushed with twisting to the right, which results in colonoscope advancement. When the colonoscope tip is advanced, the colonoscope is pulled with twisting to the left to correct bending. Step 2c. Whenever the colonoscope is excessively twisted to the right and it becomes difficult to advance the colonoscope tip, the colonoscope is pulled with twisting back into the neutral position, care being taken not to displace the colonoscope tip. Step 3. Step 2a-2c is repeated. Step 4. The colonoscope is inserted into the descending colon. The sigmoid-descending colon junction is difficult to recognize as a bend section due to the straight colonoscope insertion in the sigmoid colon. Splenic flexure (□), colonoscope manipulation and movements of colonoscope tip (brown arrows and point).

And our new insertion method was performed to determine whether the colonoscope looping rate in the sigmoid colon can be reduced compared to our conventional insertion method (Fig. 3).




Figure 3. Our conventional insertion method. The shape of the colonoscope and movements of its tip were observed by using fluoroscopy. The colonoscope tip was present in the rectosigmoid colon. The patient was placed in the left lateral position. When the lumen of the sigmoid colon was observed, the colonoscope was pushed with twisting to the right or left. This was repeated which resulted in the colonoscope looping. And after arrival of the colonoscope tip at the descending colon, the colonoscope looping was resolved, and the sigmoid colon and the colonoscope were straightened together. Splenic flexure (□), colonoscope manipulation and movements of colonoscope tip (brown arrows and point).

RESULTS

The colonoscope looping rate in the sigmoid colon was 59% (267 of the 452 patients) using our conventional insertion method but 16% (62 of the 390 patients) using our new insertion method. Thus, we could reduce the colonoscope looping rate in the sigmoid colon. And there were no complications.

DISCUSSION

These results suggest that safer colonoscope insertion is possible by using our new insertion method compared with our conventional insertion method.

We consider that the colonoscope can be straightly inserted by pushing, since the colonoscope can be straightened in the colonoscope neutral position (Fig. 1-A) each time.

1 We also consider that straight insertion through the stenotic portion of the sigmoid colon
2 is possible, since the colonoscope can be straightened on the anal side of the stenotic
3 portion each time.

4 In addition, we consider that the colonoscope can be most straightly inserted despite its
5 contact with the colon when the colonoscope neutral position is rotated 25 degrees to the
6 left compared with the colonoscope neutral position shown in Fig. 1-A.

7 8 9 **REFERENCES**

- 10
11 Awazu S, Araki R, Awazu T. 2012. A method of linear passage through the sigmoid colon
12 in colonoscopy. *Gastrointestinal Endoscopy* 75:702-704.
13 Lüning TH, Keemers-Gels ME, Barendregt WB, Tan AC, Rosman C. 2007. Colonoscopic
14 perforations: a review of 30,366 patients. *Surgical Endoscopy* 21:994-997.
15 Magdeburg R, Collet P, Post S, Kaehler G. 2008. Endoclippping of iatrogenic colonic perfo-
16 ration to avoid surgery. *Surgical Endoscopy* 22:1500-1504.
17 Shah SG, Saunders BP, Brooker JC, Williams CB. 2000. Magnetic imaging of colonosco-
18 py: an audit of looping, accuracy and ancillary maneuvers. *Gastrointestinal Endoscopy*
19 52:1-8.