A peer-reviewed version of this preprint was published in PeerJ on 11 December 2014.

View the peer-reviewed version (peerj.com/articles/687), which is the preferred citable publication unless you specifically need to cite this preprint.

Stewart SB, Koller JM, Campbell MC, Black KJ. 2014. Arterial spin labeling versus BOLD in direct challenge and drug-task interaction pharmacological fMRI. PeerJ 2:e687 https://doi.org/10.7717/peerj.687

Arterial spin labeling versus BOLD in pharmacological fMRI

A carefully controlled study allowed us to compare the sensitivity of ASL (arterial spin labeling) and BOLD (blood oxygen level dependent) fMRI for detecting the effects of the adenosine A2a antagonist tozadenant in Parkinson disease . Only ASL detected the direct effect of tozadenant. BOLD was more sensitive to a cognitive task, which (unlike most drugs) allows on-off comparisons over short periods of time. Neither ASL nor BOLD could detect a cognitive-pharmacological interaction. These results are consistent with the known relative advantages of each fMRI method, and suggest that for drug development, directly imaging pharmacodynamic effects with ASL may have advantages over cognitive-pharmacological interaction BOLD, which has hitherto been the more common approach to pharmacological fMRI.

PeerJ PrePrints

PeerJ PrePrints | http://dx.doi.org/10.7287/peerj.preprints.493v1 | CC-BY 4.0 Open Access | rec: 9 Sep 2014, publ: 9 Sep 2014

Arterial spin labeling versus BOLD in pharmacological fMRI

Running Title: ASL vs BOLD in pharmacological fMRI

Authors: Stephanie B. Stewart, MD[1, 2]
Jonathan M. Koller, BSBME, BSEE[2]
Meghan C. Campbell, PhD[1]
Kevin J. Black, MD[1,2,3,4,5]

Affiliations: Departments of [1]Neurology, [2]Psychiatry, [3]Radiology, and [4]Anatomy and Neurobiology and [5]Division of Biology and Biomedical Sciences, Washington University School of Medicine, St Louis, Missouri

Direct correspondence to Dr. Black:

Campus Box 8134
Department of Psychiatry
660 S. Euclid Ave.
St. Louis, MO 63110-1093
Telephone: (314) 362-5041
Fax: (314) 362-0168
kevin@wustl.edu

PeerJ PrePrints

Abstract

A carefully controlled study allowed us to compare the sensitivity of ASL (arterial spin labeling) and BOLD (blood oxygen level dependent) fMRI for detecting the effects of the adenosine A2a antagonist tozadenant in Parkinson disease. Only ASL detected the direct effect of tozadenant. BOLD was more sensitive to a cognitive task, which (unlike most drugs) allows on-off comparisons over short periods of time. Neither ASL nor BOLD could detect a cognitive-pharmacological interaction. These results are consistent with the known relative advantages of each fMRI method, and suggest that for drug development, directly imaging pharmacodynamic effects with ASL may have advantages over cognitive-pharmacological interaction BOLD, which has hitherto been the more common approach to pharmacological fMRI.

Introduction

Pharmacological magnetic resonance imaging (phMRI) uses fMRI to determine drug-induced changes in brain activity and has multiple applications for pharmaceutical development and efficacy testing. Before the development of functional MRI (fMRI), pharmacological brain imaging most often directly compared brain activity on drug to brain activity off drug (Herscovitch, 2001; McCulloch, 1982). Generally, phMRI studies have avoided this direct approach. Some used drugs with rapid onset and rapid decay of action, and correlated brain BOLD (blood oxygen level dependent) signal with noticeable transient physiological effects, *e.g.* repeated ratings of cocaine-induced “high”(Breiter *et al.*, 1997). Other phMRI studies used drugs with rapid uptake and rapid elimination, with sequential measurements of plasma concentration, to detect brain changes with the expected pharmacokinetics (Bloom *et al.*, 1999). Drug effects on functional connectivity have also been examined (Schwarz *et al.*, 2007). The most common phMRI approach examines the interactive effects of a drug on the

PeerJ PrePrints

BOLD signal changes induced by a cognitive or sensory stimulus (Cole *et al.*, 2012; Moeller *et al.*; Wise *et al.*). All of these study designs were motivated in part by limitations of BOLD fMRI, whose signal is nonquantitative and fluctuates artifactually over space and time (Iannetti *et al.*, 2007).

By contrast, ASL (arterial spin labeling) is an fMRI method that produces a temporally stable signal. Additionally, ASL images reflect regional cerebral blood flow (rCBF) and thus allow relatively straightforward physiological interpretation. These advantages have led some recent drug discovery phMRI studies to use ASL (Wang *et al.*, 2011; Zelaya *et al.*, 2014 [in press]). These considerations, and our experience with pharmacological PET (positron emission tomography) blood flow imaging (Black *et al.*, 1997; Black *et al.*, 2000; Black *et al.*, 2005; Black *et al.*, 2002; Hershey *et al.*, 2003; Hershey *et al.*, 2000; Hershey *et al.*, 1998), led us to choose a pure pharmacological challenge approach with perfusion fMRI for a pharmacological challenge MRI study in Parkinson disease (Black *et al.*, 2010b). However, we designed the study so that we would also have data from the more prevalent BOLD drug-task interaction design. The resulting data set allows a fair comparison of these two methods, *i.e.* subjects provided imaging data for both methods during the same imaging sessions, with similar drug concentrations, the same task, and similar total MRI acquisition times. Here we report the results of that comparison.

Materials & Methods

Study participants

Fourteen nondemented, nondepressed, ambulatory adults age 40–75 with idiopathic Parkinson disease, treated with a stable dose of levodopa but no dopamine agonists, participated in the clinical trial (registered at hhtp://clinicaltrials.gov with identifier NCT00605553). Detailed inclusion and exclusion criteria were reported previously (Black *et al.*, 2010a). The study was approved by the Washington University Human Research Protection Office (IRB) approval # 08-0059, and all subjects provided

PeerJ PrePrints

written documentation of informed consent prior to participation.

Study protocol

In this single-subject crossover study, subjects were randomly assigned to one of two treatment groups: those assigned to group 1 took 60 mg of the adenosine A2a antagonist tozadenant (SYN115) twice daily for one week, waited for a one week washout period and then took a matching placebo twice daily for one week; those assigned to group 2 participated in the reverse order. The original report included additional subjects allocated to 20mg vs placebo, but for this report we focus only on the 60mg arms.

Subjects and investigators were blind to the group assignments. Neuroimaging was performed on the last day of each treatment week. On the morning of the scan day, they did not take their usual antiparkinsonian medications, but did take the last dose of tozadenant or placebo at approximately 6:00 AM. The timing of the fMRI assessments was planned to approximately bracket the time to maximal plasma concentration of tozadenant after chronic dosing. Subjects took 200 mg of carbidopa on arrival to the imaging center and then underwent two sets of MRI assessments, once before and once during an infusion of levodopa (LD). The study design was optimized for tozadenant rather than levodopa, and the dose of levodopa was relatively low by design, so analyses examining the effect of levodopa were secondary (see Supplementary Materials).

Subject behavior

Each scanning session included two perfusion MRI (ASL) runs while the subject performed the 2-back memory task, two control ASL runs while the subject fixated on a crosshair, and two block-design BOLD runs, each with 3 fixation blocks bracketing 3 task blocks. In each session, scans were obtained in the following order: fixation ASL, 2-back ASL, 2 BOLD runs, fixation ASL, and 2-back ASL. Thus in each session the ASL scans bracketed the BOLD runs. One subject was excluded from all analyses presented here because his 2-back task performance was less than 80% accurate.

PeerJ PrePrints

Tozadenant had no statistically significant effect on 2-back performance (Campbell *et al.*, 2010).

MR image acquisition

Both BOLD and ASL MRI data were acquired on the Siemens 3T Tim Trio with matrix head coil. BOLD-sensitive echo-planar images (EPI) were obtained with flip angle 90°, echo time (TE) 27 ms, repetition time (TR) 2000ms, 36 planes with interleaved slice acquisition, field of view 256×256mm, and voxel size $(4.0\text{mm})^3$. Over a period of 4.33 min for each run, 130 volumes (frames) were acquired; the first 4 frames were discarded to ensure steady-state magnetization.

ASL images were acquired with the commercial Siemens pASL sequence (Wang *et al.*, 2003b). Fifteen echo-planar readout slices with center-to-center slice distance 7.5 mm were acquired in the AC-PC plane with 64×64 $(3.4375\text{mm})^2$ voxels in each plane, TR 2600ms, TE 13.0 msec, and flip angle 90°. An M_0 image was followed by 31 tag-control pairs for a total acquisition time for each ASL run of 2.73 min.

Brain structure was assessed from sagittal MP-RAGE acquisitions with voxel size $(1.0\text{mm})^3$, TR = 2400 msec, TE = 3.08 msec, TI = 1000 msec, flip angle = 8°. The structural images for each subject were inspected visually, images of lower quality were rejected, and the remaining 1-4 MP-RAGE images for each subject were mutually registered and averaged using a validated method (Black *et al.*).

Image preprocessing

BOLD images from each subject were preprocessed to reduce artifacts, including correction for intensity differences due to interleaved acquisition, interpolation for slice time correction, correction for head movement, and alignment to atlas space (Hershey *et al.*, 2004). Image intensity was adjusted on a frame-by-frame basis so that each frame had a whole-brain modal value of 1000 (Ojemann *et al.*, 1997). Frames were smoothed using a

PeerJ PrePrints

6mm (FWHM) Gaussian filter and resampled to $(3mm)^3$ cubic voxels. To minimize motion-related artifact, frames were removed if framewise displacement exceeded 0.9mm (Siegel *et al.*, 2014).

The 63 frames of the ASL run were smoothed using a 5.7mm (FWHM) Gaussian filter (resolution chosen to best match the final smoothing estimated from the BOLD images) and rigidly aligned using a validated method (Black *et al.*, 2001a). Cerebral blood flow (CBF) was computed in each voxel for each tag-control EPI pair as described (Wang *et al.*, 2003b). The aligned EPI images were also summed to facilitate later alignment steps, and the summed, aligned EPI images from each run were mutually aligned within each subject and summed across runs. The resulting summed EPI images from each subject were affine registered to a target image in Talairach and Tournoux space made using validated methods from these subjects' structural MR images (Hershey *et al.*, 2004). The products of the registration matrix from this step and the matrices from the within-run mutual registration step were used to resample the 31 tag–control pair CBF images from each run into atlas space images with $(3mm)^3$ cubic voxels in a single resampling step. To minimize motion-related artifact we removed tag–control pairs if framewise displacement in either EPI image exceeded 0.9mm (Siegel *et al.*, 2014). One subject's data was excluded from further analysis because over half of his frame pairs were removed due to head motion. The CBF images in atlas space from the remaining pairs were averaged to create one atlas-registered CBF image for each ASL run. Each CBF image was corrected to an idealized modal global (whole-brain) CBF of 50 mL/hg/min (Stewart *et al.*, 2014).

Statistical analysis

Analysis strategy

The analyses were designed so that each ASL–BOLD comparison included the same scan sessions from the same group of subjects, and as nearly as possible the same image smoothness. Furthermore, the images used to compare the modalities were *t* images from the same sample, and hence

PeerJ PrePrints

were commensurate. Statistical images were created for each imaging modality to examine the 2-back task effect, the interaction of the 2-back task with tozadenant, and a direct comparison of tozadenant versus placebo.

Statistical images

To identify regions of activation and deactivation, we used a mixed-effects approach with partitioned variance (Penny *et al.*, 2007). First, for each study subject, we used a voxelwise general linear model (GLM) that included main effects of task (2-back *vs*. fixation), levodopa (during *vs*. before infusion) and drug (tozadenant *vs.* placebo). For each effect analyzed (drug, 2-back task, infusion and their interactions), SPM12b software (www.fil.ion.ucl.ac.uk/spm/) generated a contrast image for each subject from ASL data, and fIDL (http://www.nil.wustl.edu/~fidl/) did the same for BOLD images (also correcting for linear drift within each run). Note for each subject, every contrast image for ASL data was derived from the same set of scans, and similarly for the BOLD data. These single-subject contrast images were used as input to second-level SPM analyses based on a voxelwise general linear model with a covariate for subject age and a factor for sex. One-tailed one-sample t tests at each voxel tested whether the single-subject contrast images at that voxel were significantly less than or greater than zero, across subjects. After thresholding at the t value corresponding to uncorrected p=.001, multiple comparisons correction was performed with the cluster false discovery rate set at p=.05. Approximate anatomical locations of peaks in the statistical images were provided by the Talairach Daemon client (www.talairach.org) (Lancaster *et al.*, 1997; Lancaster *et al.*, 2000).

Results

Cross-modality image comparison

The final resolution of the 3×3×3mm ASL and BOLD images was similar (Table 1). Total acquisition time was about 25% longer for ASL than BOLD, but acquisition time for the data actually submitted to statistical analysis

PeerJ PrePrints

was much more similar (Table 1), largely because each head movement lost 5.2sec of data in the ASL data versus 2.0sec in the BOLD data.

Task activation

The working memory task serves as a positive control, and significant regional activations were identified. The analysis using the ASL data identified one significant activation cluster (22 voxels = 0.6 ml, corrected p=0.030, peak t = 5.88 at -32, -3, 57, left middle frontal gyrus, Brodmann area [BA] 6). The analysis using the BOLD data identified 12 significant clusters; the largest cluster also included -32, -3, 57 (515 voxels = 13.9 ml, corrected p<.001, peak t = 12.29 at -40, 3, 33 (left precentral gyrus, BA6) (see Suppl. Table 1). There were no significant deactivations in the ASL data, while the analysis using the BOLD data identified 11 significant deactivation clusters (the largest had volume 2142 voxels = 57.8 ml, corrected p<.001, peak t = 12.70 at -4, -54, 12, left posterior cingulate, BA29) (see Suppl. Table 2).

Drug effect

The task-drug interaction (tozadenant × 2-back) showed no significant results for ASL or BOLD. However, the same ASL data revealed significant rCBF decreases on tozadenant in the thalamus bilaterally (Table 2, Suppl. Figure 1). There were no significant clusters of increased rCBF. As expected, the same contrast with the BOLD data found no significant clusters of activation or deactivation. Table 3 summarizes all these contrasts.

Discussion

Cognitive-pharmacological interaction is a common phMRI approach. However, in this study neither ASL nor BOLD analyses detected significant clusters for the interaction of tozadenant with 2-back task activation, whereas directly comparing rCBF on versus off drug using ASL did reveal significant differences. The drug-induced rCBF decreases detected by ASL are in the thalamus, consistent with animal studies suggesting that

PeerJ PrePrints

adenosine A2a receptor antagonists inhibit neuronal activity in the indirect pathway, including in pallidal afferents to thalamus (Black *et al.*, 2010b).

Positive controls built into the experiment confirm that the absence of significant drug effects in the BOLD analysis cannot be comfortably attributed to inadequate image quality or limited data: these same scans were quite adequate to detect significant cognitive (2-back task) effects in a pattern consistent with previous functional imaging studies on working memory (Barch *et al.*, 2012; Bledowski *et al.*, 2010). BOLD is generally more sensitive than ASL for comparisons like this one that can be made over very brief time intervals (a minute or so) (Wang *et al.*, 2003a). However, noise in BOLD data worsens as the time between activation and control acquisitions increases (Aguirre *et al.*, 2002; Ollinger *et al.*, 2001), and this temporal instability likely explains why the BOLD data could not detect direct drug effects between sessions. By contrast, the temporal stability of ASL may suit it better to measure the effects of medications, which after all often have been optimized to require only a few doses a day, and hence have slow onset and wearing off of action (Aguirre *et al.*, 2002; Wang *et al.*, 2011; Zelaya *et al.*, 2014 [in press]).

Comparing scans from different sequences was feasible here because both BOLD and ASL data were acquired during the same scan sessions in the same subjects, and because the images submitted to statistical analysis were of similar spatial smoothness. Also, in each scan session, half of the ASL scans came before and half after the two BOLD runs, so that any slowly evolving effects of practice, fatigue or drug should be similar on average for the two modalities. Limitations of this study include the imperfect matching between ASL and BOLD of total acquisition time and original voxel size. The different original voxel size is in part a technical limitation because ASL is best suited to acquiring read-out planes in inferior-to-superior order, whereas BOLD can be acquired with even and odd read-out planes interleaved.

PeerJ PrePrints

Decreased thalamic rCBF with tozadenant was also the most significant result of the previously published analysis of ASL data from this study (Black *et al.*, 2010b), but the present analysis detected fewer significant voxels. This is probably because in order to match the BOLD data, the present analysis excluded half the ASL data (acquired during additional behavior states for which were no comparable BOLD data) and smoothed the data less than in the published analysis. We now also excluded subjects with excessive movement or poor 2-back task performance, censored frames for head motion, and improved the correction for global CBF.

One additional advantage of this study comes from the following consideration. A drug that produces symptomatic effects, for instance a feeling of calm, may cause secondary effects on neuronal activity via the effect on emotional state in addition to any direct neuronal effects (including the neuronal effects that themselves produce the sense of calm). The same reasoning applies to any placebo effect that may be heightened if the subject notices any drug effect. In this study, most subjects were unable to distinguish whether they were taking active drug or placebo, allowing more straightforward interpretation of the drug's effects on neuronal activity.

Conclusions

In summary, these data offer direct, head-to-head evidence that phMRI using ASL and pure pharmacologic activation may be more sensitive than task-interaction BOLD phMRI.

Acknowledgments

The analysis reported here was supported by NIH (K24 MH087913 and T32 DA007261). The original study was funded commercially, but the sponsor did not participate in or affect this analysis or this report. There have been no other commercial or financial relationships that could be construed as a potential conflict of interest.

PeerJ PrePrints

References

Aguirre GK, Detre JA, Zarahn E, Alsop DC (2002). Experimental design and the relative sensitivity of BOLD and perfusion fMRI. *Neuroimage.* **15**(3)**:** 488-500.

Barch DM, Moore H, Nee DE, Manoach DS, Luck SJ (2012). CNTRICS imaging biomarkers selection: Working memory. *Schizophrenia bulletin* **38**(1)**:** 43-52.

Black KJ, Campbell MC, Dickerson W, Koller JM, Chung SC, Bandak SI (2010a). A randomized, double-blind, placebo-controlled cross-over trial of the adenosine 2a antagonist SYN115 in Parkinson disease. In: *Annual meeting of the American Academy of Neurology*. Toronto, CA.

Black KJ, Gado MH, Perlmutter JS (1997). PET measurement of dopamine D2 receptor-mediated changes in striatopallidal function. *Journal of Neuroscience* **17**(9)**:** 3168-3177.

Black KJ, Hershey T, Gado MH, Perlmutter JS (2000). Dopamine D_1 agonist activates temporal lobe structures in primates. *Journal of Neurophysiology* **84**(1)**:** 549-557.

Black KJ, Hershey T, Hartlein JM, Carl JL, Perlmutter JS (2005). Levodopa challenge neuroimaging of levodopa-related mood fluctuations in Parkinson's disease. *Neuropsychopharmacology* **30**(3)**:** 590-601.

PeerJ PrePrints

Black KJ, Hershey T, Koller JM, Videen TO, Mintun MA, Price JL*, et al.* (2002). A possible substrate for dopamine-related changes in mood and behavior: prefrontal and limbic effects of a D_3-preferring dopamine agonist. *Proceedings of the National Academy of Sciences of the United States of America* **99**(26)**:** 17113-17118.

Black KJ, Koller JM, Campbell MC, Gusnard DA, Bandak SI (2010b). Quantification of indirect pathway inhibition by the adenosine A 2a antagonist SYN115 in Parkinson disease. *Journal of Neuroscience* **30**(48)**:** 16284-16292.

Black KJ, Snyder AZ, Koller JM, Gado MH, Perlmutter JS (2001a). Template images for nonhuman primate neuroimaging: 1. Baboon. *Neuroimage* **14**(3)**:** 736-743.

Black KJ, Snyder AZ, Koller JM, Gado MH, Perlmutter JS (2001b). Template images for nonhuman primate neuroimaging: 1. Baboon. *Neuroimage* **14**(3)**:** 736-743.

Bledowski C, Kaiser J, Rahm B (2010). Basic operations in working memory: contributions from functional imaging studies. *Behavioural brain research* **214**(2)**:** 172-179.

Bloom AS, Hoffmann RG, Fuller SA, Pankiewicz J, Harsch HH, Stein EA (1999). Determination of drug-induced changes in functional MRI signal using a pharmacokinetic model. *Human Brain Mapping* **8:** 235-244.

Breiter HC, Gollub RL, Weisskoff RM, Kennedy DN, Makris N, Berke JD*, et al.* (1997). Acute effects of cocaine on human brain activity and emotion. *Neuron* **19:** 691-611.

PeerJ PrePrints

Campbell MC, Koller JM, Bandak SI, Black KJ (2010). Cognition in Parkinson disease: Effects of levodopa and an adenosine A_{2a} antagonist. *Journal of the International Neuropsychological Society* **16 [Suppl S1]**(Suppl S1)**:** 46.

Cole PE, Schwarz AJ, Schmidt ME (2012). Applications of imaging biomarkers in the early clinical development of central nervous system therapeutic agents. *Clinical pharmacology and therapeutics* **91**(2)**:** 315-320.

Herscovitch P (2001). Can [^{15}O]water be used to evaluate drugs? *Journal of clinical pharmacology* **41:** 11S-20S.

Hershey T, Black KJ, Carl JL, McGee-Minnich L, Snyder AZ, Perlmutter JS (2003). Long term treatment and disease severity change brain responses to levodopa in Parkinson's disease. *Journal of Neurology Neurosurgery and Psychiatry* **74**(7)**:** 844-851.

Hershey T, Black KJ, Carl JL, Perlmutter JS (2000). Dopa-induced blood flow responses in non-human primates. *Experimental Neurology* **166**(2)**:** 342-349.

Hershey T, Black KJ, Hartlein JM, Barch DM, Braver TS, Carl JL*, et al.* (2004). Cognitive-pharmacologic functional magnetic resonance imaging in tourette syndrome: a pilot study. *Biol Psychiatry* **55**(9)**:** 916-925.

Hershey T, Black KJ, Stambuk MK, Carl JL, McGee-Minnich LA, Perlmutter JS (1998). Altered thalamic response to levodopa in Parkinson's patients with dopa-induced dyskinesias. *Proceedings of the National Academy of Sciences of the United States of America* **95**(20)**:** 12016-12021.

PeerJ PrePrints

Iannetti GD, Wise RG (2007). BOLD functional MRI in disease and pharmacological studies: room for improvement? *Magn Reson.Imaging* **25**(6)**:** 978-988.

Lancaster JL, Rainey LH, Summerlin JL, Freitas CS, Fox PT, Evans AC*, et al.* (1997). Automated labeling of the human brain: a preliminary report on the development and evaluation of a forward-transform method. *Hum Brain Mapp* **5**(4)**:** 238-242.

Lancaster JL, Woldorff MG, Parsons LM, Liotti M, Freitas CS, Rainey L*, et al.* (2000). Automated Talairach atlas labels for functional brain mapping. *Human Brain Mapping* **10**(3)**:** 120-131.

McCulloch J (1982). Mapping functional alterations in the CNS with [14C]deoxyglucose. In: Iverson LL, Iverson SD, Snyder SH (ed)^(eds). *Handbook of Psychopharmacology: New Techniques in Psychopharmacology*, edn, Vol. 15. New York: Plenum. p^pp 321-410.

Moeller FG, Steinberg JL, Lane SD, Kjome KL, Ma L, Ferre S*, et al.* (2012). Increased orbitofrontal brain activation after administration of a selective adenosine A_{2A} antagonist in cocaine dependent subjects. *Frontiers in psychiatry* **3:** 44.

Ojemann JG, Akbudak E, Snyder AZ, McKinstry RC, Raichle M, Conturo TE (1997). Anatomic localization and quantitative analysis of gradient refocused echo-planar fMRI susceptibility artifacts. *Neuroimage* **6**(3)**:** 156-167.

PeerJ PrePrints

Ollinger JM, Corbetta M, Shulman GL (2001). Separating processes within a trial in event-related functional MRI II: analysis. *Neuroimage* **13**(1)**:** 218-229.

Penny W, Henson RN (2007). Analysis of variance. In: Friston K, Ashburner J, Kiebel S, Nichols T, Penny W (ed)^(eds). *Statistical Parametric Mapping: The analysis of functional brain images*, edn. London: Elsevier. p^pp 166-177.

Schwarz AJ, Gozzi A, Reese T, Bifone A (2007). In vivo mapping of functional connectivity in neurotransmitter systems using pharmacological MRI. *Neuroimage.* **34**(4)**:** 1627-1636.

Siegel JS, Power JD, Dubis JW, Vogel AC, Church JA, Schlaggar BL*, et al.* (2014). Statistical improvements in functional magnetic resonance imaging analyses produced by censoring high-motion data points. *Hum Brain Mapp* **35**(5)**:** 1981-1996.

Stewart SB, Koller JM, Campbell MC, Perlmutter JS, Black KJ (2014). Additive global cerebral blood flow normalization in arterial spin labeling perfusion imaging. *PeerJ PrePrints* **2:** e464v1.

Wang DJ, Chen Y, Fernandez-Seara MA, Detre JA (2011). Potentials and challenges for arterial spin labeling in pharmacological magnetic resonance imaging. *J Pharmacol Exp Ther* **337**(2)**:** 359-366.

Wang J, Aguirre GK, Kimberg DY, Roc AC, Li L, Detre JA (2003a). Arterial spin labeling perfusion fMRI with very low task frequency. *Magn Reson.Med.* **49**(5)**:** 796-802.

PeerJ PrePrints

Wang J, Licht DJ, Jahng GH, Liu CS, Rubin JT, Haselgrove J*, et al.* (2003b). Pediatric perfusion imaging using pulsed arterial spin labeling. *J.Magn Reson.Imaging* **18**(4)**:** 404-413.

Wise RG, Rogers R, Painter D, Bantick S, Ploghaus A, Williams P*, et al.* (2002). Combining fMRI with a pharmacokinetic model to determine which brain areas activated by painful stimulation are specifically modulated by remifentanil. *Neuroimage.* **16**(4)**:** 999-1014.

Zelaya FO, Fernández-Seara M, Black KJ, Williams SCR, Mehta MA (2014 [in press]). Perfusion in pharmacological imaging. In: Bammer R (ed)^(eds). *MR & CT Perfusion in Pharmacokinetic Imaging: Clinical Applications and Theory*, edn. Philadelphia, PA: Lippincott Williams & Wilkins. p^pp.

PeerJ PrePrints

395 **Table 1: Comparison of BOLD and ASL images**

	BOLD	ASL
Total acquisition time per scanning session	8.7 min	10.9 min
Acquisition time per session, limited to frames retained after motion censoring (mean ± SD)	8.5 ± 0.1 min	9.2 ± 1.1 min
FWHM (x × y × z) *	10.1 × 10.5 × 9.0 mm	9.4 × 10.5 × 11 mm

396 * Average of the FWHM estimates across SPM analyses.

397 **Table 2: Significant clusters of decreased rCBF on tozadenant**

	Significant clusters
cluster volume, voxels (cm^3)	25 (0.68)
p (FDR)	.004
peak t	5.67
atlas location	8, -15, 9
anatomical location of peak t	Right medial dorsal nucleus of thalamus
cluster volume, voxels (cm^3)	10 (0.27)
p (FDR)	.049
peak t	5.17
atlas location	-8, -21, 9
anatomical location of peak t	Left medial dorsal nucleus of thalamus

398 **Table includes all clusters with FDR-corrected p<.05.**

PeerJ PrePrints

Table 3: Summary of activation clusters for all contrasts

Task Contrast	Number of Significant Clusters	
	ASL	**BOLD**
2-back activation	1	12
2-back deactivation	0	11
Tozadenant × 2-back activation	0	0
Tozadenant × 2-back deactivation	0	0
Tozadenant activation	0	0
Tozadenant deactivation	2	0

PeerJ PrePrints

Supplementary Material

Supplementary Table 1: Significant activations during 2-back task (BOLD)

#	cluster volume, voxels	cluster volume, cm^3	*p* (FDR)	peak t	atlas location of peak t value	anatomical location *
1	515	13.9	<.001	12.29	−40 3 33	left precentral gyrus (BA 6)
2	471	12.7	<.001	9.80	4 12 48	right superior frontal gyrus (BA 6)
3	327	8.8	<.001	10.75	56 −54 −12	right inferior temporal gyrus (BA20)
4	224	6.0	<.001	9.40	−40 −63 −24	left posterior lobe
5	223	6.0	<.001	8.73	44 27 30	right middle frontal gyrus (BA9)
6	166	4.5	<.001	7.53	−10 −18 12	left caudate
7	163	4.4	<.001	6.38	44 −48 51	right postcentral gyrus (BA2)
8	142	3.8	<.001	13.42	32 21 6	right insula (BA 13)
9	127	3.4	<.001	12.94	−28 21 3	left claustrum
10	108	2.9	<.001	8.41	−2 −81 −27	left cerebellum
11	47	1.3	<.001	7.69	−28 −57 42	left superior parietal lobule (BA7)
12	22	0.6	.016	6.30	−38 48 18	left superior frontal gyrus (BA10)

PeerJ PrePrints

* BA, Brodmann area

Supplementary Table 2: Significant deactivations during 2-back task (BOLD)

#	cluster volume, voxels	cluster volume, cm^3	*p* (FDR)	peak t	atlas location of peak t value	anatomical location *
1	2142	57.8	<.001	12.70	4 −54 12	right posterior cingulate (BA29)
2	507	13.7	<.001	8.03	4 12 0	right caudate
3	360	9.7	<.001	7.76	−38 −18 21	left insula (BA13)
4	132	3.6	<.001	8.78	−44 −75 30	left angular gyrus (BA39)
5	104	2.8	<.001	6.72	52 −75 21	right middle temporal gyrus (BA19)
6	65	1.8	<.001	6.81	−56 0 −15	left middle temporal gyrus (BA21)
7	59	1.6	<.001	7.57	26 6 −21	right uncus (BA28)
8	46	1.2	.001	9.74	10 −51 −42	right cerebellar tonsil
9	42	1.1	.001	6.50	32 −72 −33	right pyramis
10	40	1.1	.001	6.68	−34 −18 0	left lentiform nucleus
11	29	0.8	.006	7.18	14 39 54	right superior frontal gyrus (BA8)

* BA, Brodmann area

PeerJ PrePrints

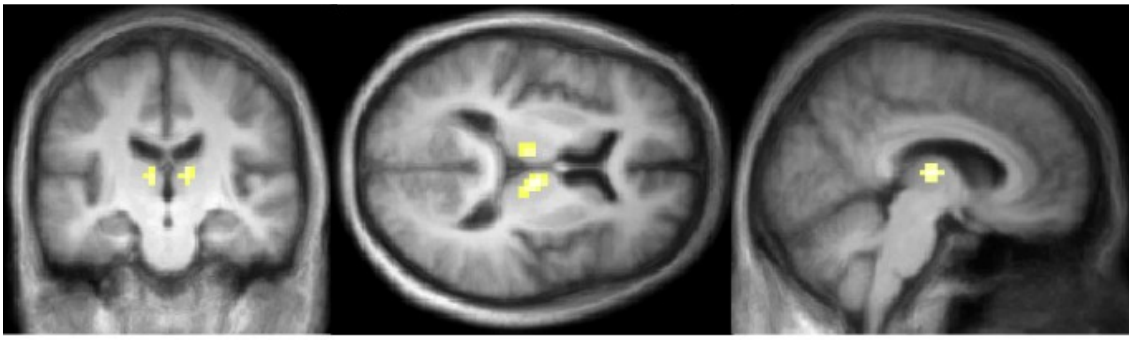

Supplementary Figure 1: Coronal, axial and sagittal sections showing the significant CBF decreases on tozadenant 60mg twice daily. Colored voxels indicate p<.001 uncorrected; the corrected *p* value is .004 for the cluster in right thalamus and .049 for the left (see also Table 2).

Supplementary Material (*continued*)

Materials & Methods (secondary levadopa analyses)

The data come from the same scans as reported in the main body of the paper. The study design was optimized for tozadenant rather than levodopa (LD), and the LD dose was relatively low, so analyses examining the effect of levodopa were secondary.

The approach was identical to that reported for the task and tozadenant analyses in the main body of the paper. To investigate the effects of LD we created statistical images of the LD effect (comparing scans acquired during the LD infusion to scans prior to infusion), of the interaction of the 2-back task with LD, and of the 3-way interaction of the 2-back task, LD and tozadenant.

Results (secondary LD analyses)

There were no significant clusters for the pure LD effect, the task-LD interaction, or the 3-way interaction in either the ASL or the BOLD images.

PeerJ PrePrints

PeerJ PrePrints