Mammalian bone palaeohistology: new data and a survey

Christian Kolb, Torsten M. Scheyer, Kristof Veitschegger, Analia M. Forasiepi, Eli Amson, Alexandra van der Geer, Lars W. van den Hoek Ostende, Shoji Hayashi, Marcelo R. Sánchez-Villagra

The interest in mammalian palaeohistology has increased dramatically in the last two decades. Starting in 1849 via descriptive approaches, it has been demonstrated that bone tissue and vascularisation types correlate with several biological variables such as ontogenetic stage, growth rate, and ecology. Mammalian bone displays a large variety of bone tissues and vascularisation patterns reaching from lamellar or parallel-fibred to fibrolamellar or woven-fibred bone, depending on taxon and individual age. Here we systematically review the knowledge and methods on mammalian bone and palaeohistology and discuss potential future research fields and techniques. We present new data on the bone microstructure of two extant marsupial species and of several extinct continental and island placental mammals. Three juvenile specimens of the dwarf island hippopotamid *Hippopotamus minor* from the Late Pleistocene of Cyprus show reticular to plexiform fibrolamellar bone. The island murid *Mikrotia magna* from the Late Miocene of Gargano, Italy displays parallel-fibred primary bone with reticular vascularisation being pervaded by irregular secondary osteons in the central part of the cortex. *Leithia* sp., the dormouse from the Pleistocene of Sicily, is characterised by a primary bone cortex consisting of lamellar bone and low vascularisation. The bone cortex of the fossil continental lagomorph *Prolagus oeningensis* and three fossil species of insular *Prolagus* displays parallel-fibred primary bone and reticular, radial as well as longitudinal vascularisation. Typical for large mammals, secondary bone in the giant rhinocerotoid *Paraceratherium* sp. from the Miocene of Turkey is represented by dense Haversian bone. The skeletochronological features of *Sinomegaceros yabei*, a large-sized deer from the Pleistocene of Japan closely related to *Megaloceros*, indicate a high growth rate. These examples and the critical summary of existing data show how bone microstructure can reveal essential information on life history evolution. The bone tissue and the skeletochronological data of the sampled island species show that there is no universal modification of bone tissue and life history specific to insular species.

PeerJ PrePrints | https://dx.doi.org/10.7287/peerj.preprints.1155v1 | CC-BY 4.0 Open Access | rec: 2 Jun 2015, publ: 2 Jun 2015

Mammalian bone palaeohistology: new data and a survey

Christian Kolb[1*], Torsten M. Scheyer[1], Kristof Veitschegger[1], Analia M. Forasiepi[2], Eli Amson[1], Alexandra van der Geer[3], Lars W. van den Hoek Ostende[3], Shoji Hayashi[4], Marcelo R. Sánchez-Villagra[1]

[1]Paläontologisches Institut und Museum der Universität Zürich, Karl Schmid-Strasse 4, CH-8006 Zürich, Switzerland (christian.kolb@pim.uzh.ch, Tel. +41(0)446342269; tscheyer@pim.uzh.ch, Tel.: +41(0)446342322; kristof.veitschegger@pim.uzh.ch, Tel.: +41(0)446342329; eli.amson@pim.uzh.ch, Tel +41(0)446342148; m.sanchez@pim.uzh.ch, Tel. +41(0)446342342)

[2] Consejo Nacional de Investigaciones Científicas y Técnicas (CONICET), Instituto Argentino de Nivología, Glaciología y Ciencias Ambientales (IANIGLA), Centro Científico y Tecnológico (CCT), Av. Ruiz Leal s/nº 5500, Mendoza-ciudad, Mendoza, Argentina (acanthodes@gmail.com, Tel. +54(261)5244253)

[3] Naturalis Biodiversity Center, P.O. Box 9517, 2300 RA Leiden, The Netherlands (alexandra.vandergeer@naturalis.nl, Tel. +31(0)717517390; lars.vandenhoekostende@naturalis.nl, Tel. +31(0)715687685*)*

[4] Osaka Museum of Natural History, Nagai Park 1-23, Higashi-Sumiyoshi-Ku, Osaka, 546-0034, Japan (hayashi@mus-nh.city.osaka.jp)

*Corresponding author

Abstract

The interest in mammalian palaeohistology has increased dramatically in the last two decades. Starting in 1849 via descriptive approaches, it has been demonstrated that bone tissue and vascularisation types correlate with several biological variables such as ontogenetic stage, growth rate, and ecology. Mammalian bone displays a large variety of bone tissues and vascularisation patterns reaching from lamellar or parallel-fibred to fibrolamellar or woven-fibred bone, depending on taxon and individual age. Here we systematically review the knowledge and methods on mammalian bone and palaeohistology and discuss potential future research fields and techniques. We present new data on the bone microstructure of two extant marsupial species and of several extinct continental and island placental mammals. Three juvenile specimens of the dwarf island hippopotamid *Hippopotamus minor* from the Late Pleistocene of Cyprus show reticular to plexiform fibrolamellar bone. The island murid *Mikrotia magna* from the Late Miocene of Gargano, Italy displays parallel-fibred primary bone with reticular vascularisation being pervaded by irregular secondary osteons in the central part of the cortex. *Leithia* sp., the dormouse from the Pleistocene of Sicily, is characterised by a primary bone cortex consisting of lamellar bone and low vascularisation. The bone cortex of the fossil continental lagomorph *Prolagus oeningensis* and three fossil species of insular *Prolagus* displays parallel-fibred primary bone and reticular, radial as well as longitudinal vascularisation. Typical for large mammals, secondary bone in the giant rhinocerotoid *Paraceratherium* sp. from the Miocene of Turkey is represented by dense Haversian bone. The skeletochronological features of *Sinomegaceros yabei*, a large-sized deer from the Pleistocene of Japan closely related to

Megaloceros, indicate a high growth rate. These examples and the critical summary of existing data show how bone microstructure can reveal essential information on life history evolution. The bone tissue and the skeletochronological data of the sampled island species show that there is no universal modification of bone tissue and life history specific to insular species.

Introduction

Histology of fossil bones (e.g. Ricqlès, 1976a; Padian, 2011) provides data to investigate life history variables such as age, sexual maturity, growth patterns, and reproductive cycles. Research on fossil vertebrate hard tissues dates back to the 19th century when it was recognised that bones and teeth are commonly very well preserved at the histological level (Quekett, 1849a; Quekett, 1849b). Since then, several descriptive surveys of different tetrapod taxa, including mammals, were published (e.g. Schaffer, 1890; Enlow & Brown, 1958; Ricqlès, 1976a; Ricqlès, 1976b; Klevezal, 1996; Marin-Moratalla et al., 2014; Prondvai et al., 2014). The study of the microstructure of highly mineralised components such as blood vessel arrangement (de Boef & Larsson, 2007) and tissue types in bones as well as teeth (e.g. Kolb et al., 2015) provides information on growth patterns and remodelling processes of hard tissues in extinct vertebrates (see also Scheyer, Klein & Sander, 2010; Chinsamy-Turan, 2012a; and Padian & Lamm, 2013 for summaries).

Mammals are a well-known group of vertebrates with a well-documented fossil record. However, until recent years and apart from a few seminal papers (Gross, 1934; Enlow & Brown, 1958; Warren, 1963; Klevezal, 1996), mammalian bone histology received little attention by biologists and palaeontologists alike compared to dinosaurs and non-mammalian synapsids (e.g.

Horner, Ricqlès & Padian, 1999; Sander et al., 2004; Chinsamy-Turan, 2012; see also Padian, 2013 for a review on Chinsamy-Turan, 2012a).

The present contribution summarizes the main aspects about the current state of knowledge on mammalian palaeohistology, presents new finds on several extant and extinct species from diverse clades, and discusses perspectives in this field of research. Literature dealing with pathologies in mammalian bone is omitted since this would go beyond the scope of this synthesis.

Bone tissue types

Bone is composed of an organic phase and an anorganic mineral phase consisting of carbonate hydroxyl apatite —$Ca_{10}(PO_4\ Ca_3)_6(OH)_2$. Being a complex and specialized connective tissue, bone, along with cartilage, forms the skeleton of all tetrapods. During fossilization, the hydroxyl group as part of the anorganic bone phase is replaced by fluorine to form carbonate fluorapatite, while the organic component, consisting mainly of Type I collagen, usually decomposes. However, the more resistant anorganic (mineral) component of the bone is only prone to minor changes and still depicts the original microstructure (Francillon-Vieillot et al., 1990; Chinsamy-Turan, 2012b).

In mammals, three main types of bone matrix are distinguished. *Woven-fibred bone* shows very low spatial arrangement. It consists of highly disorganised collagen fibres of different sizes being loosely and randomly arranged. *Parallel-fibred bone* consists of tightly packed collagen fibrils arranged in parallel. *Lamellar bone* shows the highest spatial organisation. It consists of thin layers (lamellae) of closely packed collagen fibres. Both parallel-fibred and lamellar bone are indicative of relatively low growth rates (Francillon-Vieillot et al.,

1990; Huttenlocker , Woodward & Hall, 2013). Bromage et al. (2009) confirmed that lamellar bone is an incremental tissue, with one lamella formed in the species-specific time dependency of the formation of long-period increments (striae of Retzius) in enamel. The authors showed as well a negative correlation between osteocyte density in bone and body mass and therefore suggested a central autonomic regulatory control mechanism to the coordination of organismal life history and body mass.

A bone complex composed of woven-fibred scaffolding and intervening primary osteons of varying orientations, i.e. parallel-fibred or lamellar bone, is defined as *fibrolamellar bone* (Figs. 1B, 1C, 1E, 1F) (Ricqlès, 1974a) or fibrolamellar complex (FLC; Ricqlès et al., 1991; Margerie, Cubo & Castanet, 2002). According to its vascular orientation, three main types of fibrolamellar bone are distinguished: *Laminar bone* shows an almost uniform circumferential orientation of vascular canals. In case laminar canals are connected by radial ones forming a dense anastomosing network, the pattern is called *plexiform* (Figs. 1B, 1C, 1E, 1F). An anastomosing network showing random organisation with oblique orientations is defined as reticular. Moreover, a radial arrangement of vascular canals is called *radiating* or *radial bone* (Francillon-Vieillot et al., 1990; Chinsamy-Turan, 2012b; Huttenlocker, Woodward & Hall, 2013).

Amprino identified for the first time a relationship between bone tissue type and growth rate in vertebrates, what is now called Amprino's rule (Amprino, 1947). This was a milestone for the development of a modern biological approach in palaeohistology, and was tested in several studies on extant birds (Castanet et al., 2000; Margerie, Cubo & Castanet, 2002; Margerie et al., 2004). He observed that in slow growing animals or animals in late stages of ontogeny, periosteal bone is generally denser, less vascularised, and shows higher spatial arrangement. By

contrast, in fast growing animals such as mammals or in juveniles, periosteal bone is less dense and more vascularised with a high number of primary osteons, which in turn become embedded in a matrix of parallel-fibred or lamellar bone, constituting what was originally called the fibrolamellar complex by Ricqlès (1975) and subsequent authors (e.g. Köhler & Moyà-Solà, 2009; Marin-Moratalla, Jordana & Köhler, 2013). Later studies also demonstrated a relationship between periosteal growth rate and pattern of vascularisation, i.e. that growth is positively correlated with the degree of radially organised vascularisation (Margerie et al., 2004; see also Lee et al., 2013).

Stein & Prondvai (2013) found, by investigating longitudinal thin sections of sauropod long bones, that the amount of woven bone in the primary complex has been largely overestimated (e.g., Klein & Sander 2008), questioning former arguments on the biology and life history of sauropod dinosaurs. Similarly, Kolb et al. (2015) showed, via longitudinal thin sections, that in the giant deer *Megaloceros giganteus* the amount of woven-fibred bone within the fibrolamellar complex (FLC) is easily overestimated as well.

Growth marks and skeletochronology

Different types of growth marks in the bone cortex are distinguished in the osteohistological literature. They are deposited cyclically, usually occurring within lamellar or parallel-fibred bone. All kinds of growth marks indicate a change in growth rate or a complete arrest of growth.

Growth zones can be composed of any bone type or vascular pattern and represent a period of relatively elevated growth rate. *Annuli* indicate a period of relatively slower growth and consist of parallel-fibred or lamellar bone. *Lines of arrested growth* (LAGs) are thin,

semitranslucent to opaque bands (Huttenlocker, Woodward & Hall, 2013) under linear or crossed polarised light indicating a complete cessation of growth. In case they have not been obliterated by bone resorption or remodelling processes, they appear as thin and almost or completely opaque bands and comprise the whole circumference of the bone cortex. In all groups of mammals, except those reaching skeletal maturity within their first year of life, lines of arrested growth occur (Morris, 1970; Frylestam & Schantz, 1977; Buffrenil, 1982; Chinsamy, Rich & Vickers-Rich, 1998; Klevezal, 1996; Castanet et al., 2004; Köhler et al., 2012). It has repeatedly been confirmed and is now widely accepted that LAGs are deposited annually (e. g. Castanet & Smirina, 1990; Buffrénil & Castanet, 2000; Castanet, 1994; Marangoni et al., 2009; Chinsamy-Turan, 2012b) and independently of metabolic rate and climatic background (Köhler et al., 2012; Huttenlocker, Woodward & Hall, 2013) and therefore they can be used for age estimations, estimates of age at sexual or skeletal maturity, and growth rate analysis.

Castanet et al. (2004) studied LAGs in long bones, mandibles, and tooth cementum (M2 and M3) of captive specimens of known age of the mouse lemur, *Microcebus murinus*. The 43 male and 23 female specimens sampled ranged from juveniles to 11-year-old adults, for which LAG counts and ages correlated best in the tibiae. In individuals older than seven years the correlation decreased, leading to an age underestimation of three to four years and demonstrating limitations of skeletochronology in long bones (Klevezal, 1996; Castanet, 2006). Additionally, animals exposed to an artificially accelerated photoperiodic regimen (a 10-month cycle) show a higher number of LAGs than animals of the same true age in which a yearly photoperiod is maintained. According to that, there is strong evidence that photoperiodicity is an essential factor for the deposition of LAGs rather than environmental factors (see also Woodward, Padian & Lee, 2013).

Köhler et al. (2012) additionally demonstrated that the annual formation of LAGs is present throughout ruminants and that a cyclic arrest of growth in bone is mainly triggered by hormonal cues rather than environmental stresses. By confirming seasonal deposition of LAGs throughout ruminants, the general occurrence of LAGs in homeothermic endotherms has been confirmed, precluding the use of lines of arrested growth as an indicator of ectothermy.

Different kinds of processes in the cortex potentially remove parts of the growth record and may erase early LAGs. One of those processes is the substitution of primary bone tissue by secondary bone tissue in areas where resorption previously occurred. Secondary bone can appear as *Haversian bone* (Fig. 1I) consisting of clustered Haversian systems as a response to damage such as microcracks or around the medullary cavity forming endosteal lamellar bone as a response to ontogenetic changes in bone shape, i.e. bone drift (Enlow, 1962).

Several approaches to retrocalculate the lost information have been attempted and there are two ways of retrocalculating missing years. First, in case an appropriate ontogenetic growth series sampling is not available, it is possible to do arithmetic estimates of the missing intervals, done first for dinosaurs (e.g. Sander & Tückmantel, 2003; Horner & Padian, 2004; Erickson et al., 2004). The second approach is the superimposition of thin sections of long bones of different ontogenetic stages as, again done first for dinosaurs (e.g. Horner, Ricqlès & Padian, 2000; Bybee, Lee & Lamm, 2006; Lee & Werning, 2008; Erickson, 2014; see also Woodward, Padian & Lee, 2013 for more methodological details).

Marin-Moratalla, Jordana & Köhler (2013) were the first to apply the superimposition method to mammals using anteroposterior diameters of successive growth rings in five antelope (*Addax*) femora of different ages. They found that the first LAG in adult specimens fits the second growth cycle of juveniles, indicating that the first LAG is lost by resorption throughout

ontogeny. On one hand, this allowed estimates of age at death by counting all the rest lines in the bone cortex and increasing the LAG count by one. On the other hand, it was possible to estimate age at sexual maturity. When an animal becomes sexually or somatically mature, this is indicated by the deposition of a narrow layer of avascular lamellar bone, called the *outer circumferential layer* (OCL, Ponton et al., 2004; Figs. 1B, 1C), also referred to as the *external fundamental system* (EFS, *sensu* Horner, Ricqlès & Padian, 1999; see also Woodward, Padian & Lee, 2013). Given that Cormack (1987) uses the term "outer circumferential lamellae" (p. 305), we follow Ponton et al. (2004) in using the term outer circumferential layer (OCL) instead of EFS. Marin-Moratalla, Jordana & Köhler (2013) interpreted the transition from the FLC to the OCL to represent attainment of sexual maturity, since in the extant antelope *Addax* maturity estimates correlate well with individual tooth eruption and wear stages, as well as life history data. Therefore, the authors could show that in antelopes it is possible to determine age at sexual maturity and death. However, a recent study by Kolb et al. (2015) on fossil and extant cervids showed that the use of the OCL as a marker of sexual maturity can be misleading. Maturity estimates in extant cervids based on bone microstructure corresponded much more with the timing of the attainment of skeletal maturity, and, therefore, it represents skeletal rather than sexual maturity in cervids.

Material and methods

In order to contribute to a more complete picture of mammalian palaeohistology, long bones of the following additional mammalian taxa of which the bone histological characteristics are not or only poorly documented in the literature, including several taxa of extinct insular mammals, have been sampled (Table 1): The extant white-eared opossum *Didelphis albiventris*

and the thick-tailed opossum *Lutreolina crassicautada*, the giant deer *Megaloceros giganteus* from the Late Pleistocene of Ireland, the Asian giant deer *Sinomegaceros yabei* from the Late Pleistocene of Japan, the extant southern pudu *Pudu* puda, the Cyprus dwarf hippopotamid *Hippopotamus minor* from the Late Pleistocene of Cyprus, the dormouse *Leithia* sp. from the Pleistocene of Sicily, the giant hornless rhinocerotoid *Paraceratherium* sp. from the Late Oligocene of Turkey, the continental pika *Prolagus oeningensis* from the Middle Miocene of La Grive, France, and the Sardinian pika *Prolagus sardus* from the Late Pleistocene. From the Late Miocene of Gargano, Italy, the following material was sampled: The galericine insectivore *Deinogalerix* sp., the giant murid *Mikrotia magna*, as well as the giant pikas *Prolagus apricenicus* and *Prolagus imperialis*. Ontogenetic stages in long bones have been determined by the state of epiphyseal fusion (Habermehl, 1985).

Following standard procedures, bones were coated and impregnated with epoxy resin (Araldite or Technovit) prior to sawing and grinding. Long bones were transversely sectioned at mid-shaft where the growth record is most complete (e.g. Sander & Andrassy 2006; Kolb et al., 2015). Long bones of *Megaloceros giganteus* were also sampled by using a diamond-studded core drill, with sampled cores being subsequently processed (Sander & Andrassy, 2006; Stein & Sander, 2009). Sections were observed in normal transmitted and cross-polarised light using a Leica DM 2500 M composite microscope equipped with Leica DFC 420 C digital camera. Phylogenies have been produced using Mesquite 3.02© (Maddison & Maddison, 2015) and Adobe Illustrator CS5©.

Mammalian bone histology – works before 1935

The initial contribution on the bone palaeohistology of mammals was performed by Quekett (1849a, 1849b) as part of a comprehensive study dealing with the bone cortex of not only mammals but also fish, reptiles, and birds. He described mammalian long bone tissue comprising the fossil proboscidean *Mastodon*, the fossil xenarthran *Megatherium*, and humans to show Haversian canals, bony laminae, bone-cells, and canaliculi as well as a the typical three layered composition of cranial bones, ribs, and scapulae with two thin compact layers and one inner cancellous layer. Aeby (1878) concentrated on taphonomical aspects and compared bone tissue of reptiles, birds, and mammals. Kiprijanoff (1883) described in a comparative study of fossil material from Russia the bone cortex of *Bos primigenius*. Schaffer (1890) described the bone tissue of several mammalian taxa, including sirenians from the Eocene, Oligocene, and Miocene (*Halitherium*), a proboscidean from the Miocene (*Mastodon*), an undetermined fossil cetacean, and artiodactyls (an undetermined artiodactyl referred to an antelope and to *Hippopotamus*, both from the Pliocene). Schaffer also investigated Artiodactyla (*Sus scrofa,Capreolus*), Carnivora (*Ursus spelaeus*), Rodentia (*Arvicola*), as well as undetermined long and skull bones, all from the Pleistocene. Nopcsa and Heidsieck (1933) studied the bone tissue in ribs of dinosaurs, ichthyosaurs and therapsids (dicynodonts). Small individuals of *Dicynodon* and *Lystrosaurus* consist of "unlaminated" bone (p. 222) without secondary Haversian bone, whereas full-grown individuals exposed lamellar primary bone tissue with Haversian systems. Nopcsa and Heidsieck (1934) studied apart from reptile bones, ribs of sirenians (*Halitherium*). In his comparative work, Gross (1934) studied the bone cortex of a dicynodont (*Kannemeyeria*) and of the proboscidean *Mammuthus*.

Bone histology of extinct and extant synapsid clades

Non-therapsid synapsids- More than 320 Myr ago during the Carboniferous, reptilian-grade amniotes and synapsids, the lineage leading to mammals including basal forms such as edaphosaurids and sphenacodontids (Figs. 2, 3), diverged (Huttenlocker & Rega, 2012). Because of their phylogenetic position, the understanding of the evolution and structure of their skeleton is essential, since the anamniote-amniote transition was accompanied by the transition from a mainly amphibious to a terrestrial biomechanical regime and life cycle (Romer, 1957; Romer, 1958; Germain & Laurin, 2005). In order to decipher essential life history parameters and especially thermophysiology in basal synapsids, several authors studied the microstructure of their long bones and neural spines comparing them to extant mammals and birds (Enlow & Brown, 1957; Enlow & Brown 1958; Peabody, 1961; Warren, 1963; Ricqlès, 1974a; Ricqlès, 1976a; Bennett & Ruben, 1986). Cyclic and regularly lamellated ("lamellar-zonal") bone tissues in early edaphosaurids and sphenacodontids revealed similarity in bone tissue type to extant reptiles and amphibians (Ricqlès, 1974a; Ricqlès, 1974b; Ricqlès, 1976; Enlow, 1969). Huttenlocker (2008) noted bone histological differences between sphenacodontids and edaphosaurids. Sphenacodontids show fibrolamellar (see also Shelton et al., 2013) or parallel-fibred bone, whereas edaphosaurids are mainly characterised by lamellar-zonal bone. In conclusion, basal synapsids display a histological organisation that is suggestive of slow growth (Huttenlocker & Rega, 2012). Peabody (1961) and Warren (1963) showed the occurrence and skeletochronological relevance of growth marks in Palaeozoic synapsids, while Ricqlès (1969; 1972; 1974a; 1974b; 1975; 1976a; 1976b) studied several basal synapsid taxa in a series of publications. Vickaryous and Sire (2009) reviewed the integumentary skeleton of tetrapods and mentioned varanopid osteoderms to have a block-like morphology, organised into multiple transverse rows in the cervical and pectoral regions. Bone compactness profiles are used in more

recent publications to infer habitat and ecology (e.g. Germain & Laurin, 2005; Kriloff et al., 2008). Growth and mechanics of unusual skeletal structures are discussed by Rega et al. (2005), Huttenlocker, Rega & Sumida (2010), and Huttenlocker, Mazierski & Reisz (2011). Laurin & Buffrénil (2015) studied the histology and compactness of ophiacodontid bone tissue. *Clepsydrops collettii*, a Late Carboniferous ophiacodontid, displayed a thin, compact cortex lacking a medullary spongiosa, therefore suggesting a terrestrial lifestyle. An optimisation of inferred lifestyle of other early stegocephalians (based on bone microanatomy) indicated that the first amniotes were terrestrial. The Early Permian *Ophiacodon uniformis* showed a thicker cortex with few resorption cavities and bone trabeculae surrounding the free medullary cavity, thus indicating a possibly secondary amphibious lifestyle. Shelton & Sander (2015) showed the existence of highly vascularised fibrolamellar bone in *Ophiacodon* by sampling an ontogenetic series of humeri and additional femora, and therefore providing evidence for fast skeletal growth. Hence, they suggested to set the evolutionary origin of modern mammalian endothermy and high skeletal growth rates back to the Early Permian.

Dicynodontia – A large amount of studies on therapsid histology deals with dicynodont long bones, cranial bones, and ribs. Early work on the bone histology of several dicynodont genera has been performed by Nopcsa & Heidsieck (1933), Gross (1934), Enlow & Brown (1957), Enlow (1969), Ricqlès (1972; 1975; 1976a). More recent work contributed essentially to a better understanding of general dicynodont histology, containing studies on isolated bones of several individuals, several skeletal elements of one individual or dicynodont biomechanics (e.g. Chinsamy & Rubidge, 1993; Ray & Chinsamy, 2004; Ray, Chinsamy & Bandyopadhyay, 2005; Green, Schweitzer & Lamm, 2010; Ray, Bandyopadhyay & Appana, 2010; Botha-Brink & Angielczyk, 2010; Botha-Brink & Angielczyk 2010; Jasinoski, Rayfield & Chinsamy, 2010a;

Jasinoski, Rayfield & Chinsamy, 2010b; Chinsamy-Turan, 2012b; Nasterlack, Canoville & Chinsamy, 2012; Ray, Botha-Brink & Chinsamy-Turan, 2012). All authors agree on the fact that dicynodonts share primary bone tissue that consists of mainly fibrolamellar bone with a plexiform to laminar arrangement of vascular canals, suggesting overall fast rates of growth and high metabolic demands. Uninterrupted fibrolamellar bone in early ontogenetic stages and annuli, as well as LAGs only appearing during later stages of ontogeny (50 % of adult size), characterise several dicynodont taxa (Ray & Chinsamy, 2004; Botha-Brink & Angielczyk 2010; see also Ray, Botha-Brink & Chinsamy-Turan, 2012b). The occurrence of parallel-fibred bone in the periphery of the cortex indicates a decrease in growth rate suggesting onset of reproductive maturity (e.g. Castanet & Baez, 1991; Sander, 2000; Chinsamy-Turan, 2012). Peripheral rest lines in a few genera suggest asymptotic growth (Green, Schweitzer & Lamm, 2010). For some taxa it was possible to determine ontogenetic stages by bone histological features (Ray & Chinsamy, 2004; Ray, Chinsamy & Bandyopadhyay, 2005; Ray, Bandyopadhyay & Appana, 2010). Most dicynodonts are characterised by a thick bone cortex independent of body size suggesting a fossorial life style or digging habits (Botha-Brink & Angielczyk, 2010), whereas the life style of some taxa remains unclear (Germain & Laurin, 2005; Ray, Bandyopadhyay & Appana, 2010; Nasterlack, Canoville & Chinsamy, 2012).

Gorgonopsia and Therocephalia – Compared to other non-mammalian synapsids, sampling of the Middle to Late Permian carnivorous gorgonopsians and the Permotriassic therocephalians has been more limited (Botha & Chinsamy, 2000; Botha & Chinsamy, 2004; Botha & Chinsamy, 2005; Ray, Botha & Chinsamy, 2004; Chinsamy & Abdala, 2008; Botha-Brink, Abdala & Chinsamy, 2012; Sigurdsen et al., 2012; Chinsamy-Turan, 2012b; Huttenlocker & Botha-Brink, 2013; Huttenlocker & Botha-Brink 2014). The earliest contributions on gorgonopsian and

therocephalian bone histology were performed by Ricqlès (1969; 1975; 1978). He found fibrolamellar bone in two therocephalian species and in the long bones of five gorgonopsian taxa with partially thick compacta and mainly longitudinal vascularisation. The histological traits found suggested differential growth rates between a basal therocephalian from the Middle Permian of South Africa and a more derived Late Permian whaitsiid therocephalian. Because of comparatively higher vascularisation in the radius of the whaitsiid, Ricqlès (1969) suggested that therocephalians might have grown at higher rates later in their phylogeny. Recently, Huttenlocker and Botha-Brink (2014) performed a phylogenetic survey of limb bone histology in therocephalians from the Middle Permian through the Middle Triassic of the Karoo Basin, South Africa. They sampled eighty limb bones representing eleven genera of therocephalians using skeletal growth, including cortical vascularity and mean primary osteon diameters as histological indicators, and assessed for correlations with other biologically significant variables (e.g. size and robustness). Smaller-bodied descendants tended to have lower vascularity than their phylogenetically larger-bodied ancestors. Bone wall thickness tended to be high in early therocephalians and lower in gracile-limbed baurioid therocephalians. However, clade-level patterns deviated from previously studied within-lineage patterns (e.g. *Moschorhinus* displayed higher vascularity in the Triassic than in the Permian despite its smaller size). Therefore, Huttenlocker and Botha-Brink (2014) argued for a synergistic model of size reductions for Triassic therocephalians, influenced by within-lineage heterochronic shifts in survivor taxa and phylogenetically inferred survival of small-bodied taxa that had evolved short growth durations.

Non-mammalian cynodonts – Cynodonts represent the last major synapsid lineage to appear in earth history with mammals as living representatives (Fig. 2). Many articles have been published

on non-mammalian cynodont histology in recent years (e.g. Ricqlès, 1969; Botha & Chinsamy 2000; Botha & Chinsamy, 2004; Botha & Chinsamy, 2005; Ray, Botha & Chinsamy, 2004; Chinsamy & Abdala, 2008; Botha-Brink, Abdala & Chinsamy, 2012; Chinsamy-Turan, 2012b). Fibrolamellar bone is present to a varying degree in all cynodonts. Considerable variation in vascular density and orientation and the presence/absence of growth marks such as LAGs are evident. When observed within the phylogenetic context, there is an overall increase in bone deposition rate. This is indicated by an increasing prevalence of highly vascularised fibrolamellar bone in phylogenetic later cynodonts (Botha-Brink, Abdala & Chinsamy, 2012). Several factors are discussed to influence the microstructure and therefore being responsible for the aforementioned variability: phylogeny, biomechanics, ontogeny, body size, lifestyle preferences, and environmental influences (Cubo et al., 2005; Kriloff et al., 2008; Botha-Brink, Abdala & Chinsamy, 2012). Padian (2013) emphasises that the correlation between fibrolamellar bone and high growth rates as well as endothermy is still valid, although fibrolamellar bone is known to occur in rare cases in ectothermic reptiles such as crocodiles and turtles.

Multituberculata and early mammals – Studies on multituberculate (see Fig. 3 for mammalian groups discussed below) and in general stem mammalian histology are scarce. Enlow & Brown (1958) described the section of a mandible of *Ptilodus*. Its cortex consisted of lamellar bone with a central region of indistinct and unorganised lamellae, in which lacunae and cell spaces as well as radial vascular canals were present. Morphological studies have suggested different kinds of locomotion within the group (saltatorial, fossorial, scansorial, and arboreal; Kielan-Jaworowska, Zifelli & Luo, 2004), which might be reflected in the microstructure of the appendicular bones. Chinsamy & Hurum (2006) analysed in a comparative study the bone tissue of long bones and one rib of multituberculates and early mammals. They showed that *Morganucodon* and

multituberculates (*Kryptobataar*, *Nemegtbataar*) have been characterised by fibrolamellar/woven-fibred bone at early stages of ontogeny and later on by parallel-fibred or lamellar bone. These finds pointed towards relatively high rates compared to the late Mesozoic eutherians *Zalambdalestes* and *Barunlestes* with periodic growth pauses as indicated by the occurrence of LAGs. Comparisons of morganucodontid and early mammalian bone microstructure with that of non-mammalian cynodonts, extant monotremes, and placentals indicated significant differences in the rate of osteogenesis in the various groups. The authors concluded multituberculates and Mesozoic eutherians to have had slower growth rates than modern monotremes and placentals and that the sustained, uninterrupted bone formation among multituberculates may have been an adaptive attribute prior to the K−Pg event, but that a flexible growth strategy implying periodic growth pauses of the early eutherians was more advantageous thereafter.

Monotremata – Monotremes are represented today by three genera (*Ornithorynchus*, *Tachyglossus*, and *Zaglossus*) of specialized skeletal morphology. Their poor fossil record includes material from Australia and South America (Pascual et al., 1992; Musser and Archer 1998). Accordingly, the histology of monotremes has been scarcely studied. Enlow and Brown (1958) were the first to describe sections of long bones and ribs of *Platypus* and *Echidna*. Chinsamy & Hurum (2006) described the femoral bone tissue of *Ornithorhynchus* as being a mixture of woven-fibred bone with lamellar bone deposits. Additionally, large parts of the compacta consisted of compacted coarse cancellous bone. The type of vascularisation and the orientation of the vascular channels varied from simple blood vessels with longitudinal, circular and radial orientations to primary osteons with longitudinal and reticular arrangements. Only isolated secondary osteons were present.

Marsupialia – Despite marsupials are the second most diverse group of living mammals, their bone histology is poorly studied so far. Early contributions are those of Enlow & Brown (1958) and Singh (1974) on the marsupial *Didelphis*. Our study of new samples of the white-eared opossum *Didelphis albiventris* and the latrine opossum *Lutreolina crassicaudata* (Table 1) essentially confirms their observations.

The bone cortex of *Didelphis* long bones is characterised by a compacta surrounding the medullary cavity. The bone matrix is dominated by parallel-fibered bone (Figs. 4A-C). Towards the inner part, the amount of woven-fibered bone increases (Fig. 4C). In most specimens remodelling is restricted to isolated secondary osteons as described by Enlow & Brown (1958). In specimen PIMUZ A/V 5278, remodelling is abundant in the central part of the cortex, being formed by Haversian bone with obliquely oriented and irregularly shaped secondary osteons. Inner and outer circumferential layers are present. The inner circumferential layer consists of lamellar bone. The outer circumferential layer is dominated by parallel-fibered bone. The thickness of this layer varies between specimens. Except in one specimen showing one LAG, no LAGs are present in the analysed specimens suggesting constant growth rates. The bone cortex is well vascularised up to the outer part of the cortex (see also Enlow & Brown, 1958), with an irregular pattern, i.e. radial, oblique, but mainly longitudinal primary vascular canals. *Lutreolina* shows a primary bone matrix that is dominated by parallel-fibered bone with simple primary longitudinal and radial to oblique vascular canals (Figs. 4D-F). Remodelled areas are characterised by partially oblique secondary osteons (Fig. 4F). The inner circumferential layer is thin and formed by lamellar bone. The outer circumferential layer is, if present, formed by parallel-fibered bone. LAGs are not developed. The vascularity is less dense than in *Didelphis*.

The combination of parallel-fibered bone with low vascularisation suggests slow apposition rates (Chinsamy-Turan, 2012b; Huttenlocker, Woodward & Hall, 2013).

Xenarthra – Early contributions on xenarthran bone histology are Quekett (1849; 1855) and Enlow and Brown (1958). Because dermal armour is an outstanding feature of xenarthrans, several studies focussed on the histology of osteoderms and dermal ossicles (e.g. Wolf, 2007; Wolf, 2008; Chávez-Aponte et al., 2008; Hill, 2006; Vickaryous & Hall, 2006; Krmpotic et al., 2009; Vickaryous & Sire, 2009; Wolf, Kalthoff & Sander, 2012; Da Costa Pereira et al., 2012). These data shed light on soft tissue structures of extinct xenarthrans, their phylogenetic relationships as well as their functional morphology, which otherwise are not available. The most detailed study up to date dealing with xenarthran long bone histology was performed by Straehl et al., 2013 (but see also Ricqlès, Taquet & Buffrénil, 2009). Straehl and colleagues sampled sixty-seven long bones of nineteen genera and twenty-two xenarthran species and studied bone microstructure as well as bone compactness trends. Primary bone tissue consists of a mixture of woven, parallel-fibred and lamellar bone. Irregularly shaped vascular canals show longitudinal, reticular or radial orientation. Anteaters are the only sampled taxa showing laminar orientation. Armadillo long bones are characterised by obliquely oriented secondary osteons in transverse sections, reflecting their complex morphology. LAGs are common in xenarthrans although being restricted to the outermost part of the bone cortex in armadillo long bones. Moreover, cingulates (armadillos and closely relative extinct taxa) show lower bone compactness than pilosans (sloths) and an allometric relationship between humeral and femoral compactness. Straehl and colleagues emphasise that remodelling is more developed in larger taxa as indicated by dense Haversian bone in adult specimens and discuss increased loading as a possible cause. Amson et al. (2014) assessed the timing of acquisition of osteosclerosis (increase in bone compactness) and

pachyostosis (increase in bone volume) in long bones and ribs of the aquatic sloth *Thalassocnus* from the Neogene of Peru as the main osteohistological modifications of terrestrial tetrapods returning to water. They showed that such modifications can occur during a short geological time span, i.e. *ca* 4 Ma. Furthermore, the strongly remodelled nature of xenarthran bone histology allowed the reassignment of a rib previously ascribed to a sirenian to the aquatic sloth (Amson et al., 2015).

Afrotheria – Early contributions on the bone histology of afrotherians are Aeby (1878) and Schaffer (1890) on sirenians and proboscideans, Nopcsa & Heidsieck (1934) on sirenians, Vanderhoof (1937), Enlow & Brown (1958), Kaiser (1960), Mitchell (1963; 1964) on sirenians and desmostylians, and Ezra & Cook (1959) as well as Cook, Brooks & Ezra-Cohn (1962) on elephantids. Ricqlès & Buffrénil (1995) described pachyosteosclerosis in the sirenian *Hydrodamalis gigas*. Buffrenil et al. (2008; 2010) studied the ribs of 15 extant and extinct sirenian species representing 13 genera, one desmostylian, and 53 specimens of 42 extant species of terrestrial, aquatic or amphibious mammals. Primary bone tissue in young specimens is constituted by fibrolamellar bone, whereas with increasing age, parallel-fibred bone tissue with longitudinal vascular canals and frequent LAGs is deposited. The authors showed that pachyostosis is subsequently regressed during evolution of the clade. In contrast, only by the end of the Eocene, osteosclerosis was fully developed. It was argued that variable degrees of pachyostosis and osteosclerosis in extinct and extant sirenians were caused by similar heterochronic mechanisms bearing on the timing of osteoblast activity. Hayashi et al. (2013) analysed the histology of long bones, ribs, and vertebrae of four genera of desmostylians (usually considered as tethytherians, but see Cooper et al., 2014) and 108 specimens of extant taxa (ribs: 19 taxa, humeri: 62 taxa, femora: 16 taxa, vertebrae: 11 taxa) with various phylogenetic positions

and ecologies by using thin sections and CT-scan data. Primary bone tissue in desmostylians consisted of parallel-fibred bone with multiple LAGs. By comparisons with extant mammals, they found that *Behemetops* and *Palaeoparadoxia* show osteosclerosis, *Ashoroa* pachyosteosclerosis (i.e. a combination of increase in bone volume and compactness), while *Desmostylus* shows an osteoporotic-like pattern (i.e. decrease in bone compactness) instead. Since it is known from extant mammals that bone mass increase provides hydrostatic buoyancy and body trim control suitable for passive swimmers and shallow divers, whereas spongy bones are associated with hydrodynamic buoyancy control in active swimmers, they concluded that all desmostylians achieved an essentially aquatic lifestyle. However, the basal taxa *Behemotops*, *Paleoparadoxia* and *Ashoroa* could be interpreted as shallow water swimmers hovering slowly or walking on the bottom, whereas the derived taxon *Desmostylus* was a more active swimmer. The study has therefore shown that desmostylians are the second mammalian group after cetaceans to show a shift from bone mass increase to decrease during their evolutionary history.

As several tethytherian taxa are aquatic, the question of the ancestral lifestyle of the clade was raised. A femur and a humerus of the Eocene proboscidean *Numidotherium* were sampled by Mahboubi et al. (2014). These authors recognised “large medullar cavities” (p. 506), which was considered as suggestive of terrestrial habits. However, the illustrations provided by Mahboubi et al. (2014) show no opened medullary cavity, as trabecular bone occupies most of the cross-sectional area (labelled “medullary bone” by Mahboubi et al., 2014: Fig. 5).

Sander & Andrassy (2006) described the bone tissue of *Mammuthus primigenius* long bones as laminar fibrolamellar bone. Due to poor preservation of the fossil bone tissue, the authors have not been able to definitely confirm the occurrence of LAGs. The valuable study of Curtin et al. (2012) dealt with two aspects of bone histology. First, they described for the first

time the bone tissue of fifteen bones (femora and tibiae) of eleven specimens of late-term-fetal, neonatal, and young juvenile extant and extinct elephantids representing four species, including the insular dwarf mammoth *Mammuthus exilis* from the Late Pleistocene of Santa Rosa Island of the Californian Channel Islands. The bone tissue they found was predominantly laminar fibrolamellar bone. Remarkable was a distinct change in tissue microstructure marking the boundary between prenatal and postnatal bone deposition, i.e. a higher amount of large longitudinal vascular canals suggesting slightly higher postnatal growth rates. Secondly, besides histological thin sections, Curtin and colleagues employed synchrotron microtomography (SR-µCT) for noninvasively obtaining high-resolution image-"slices". They showed that, in comparison to histological sectioning, the SR-µCT data lack shrinkage, distortion or loss of tissue, as is usually the case in histological sections. However, they stated that the quality of histological detail observable is by far superior in histological thin sections. The virtual microtomography enabled the authors to rank specimens by ontogenetic stage and quantified vascular patterns. They showed that bones of the Columbian mammoth, *M. columbi* had the thickest and largest number of laminae, whereas the insular dwarf mammoth, *M. exilis*, was characterised by its variability in that regard. The authors concluded that, qualitatively, patterns of early bone growth in elephantids are similar to those of juveniles of other tetrapods, including dinosaurs.

Notoungulata – Notoungulates are an extinct, largely diverse, endemic group of Cenozoic South American mammals, ecologically similar to current hoofed ungulates. Only four taxa (*Toxodon*, *Nesodon*, *Mesotherium*, and *Paedotherium*) were subject to histological studies (Ricqlès, Taquet & Buffrénil, 2009; Forasiepi et al., 2014; Tomassini et al., 2014) from the more than 150 species recognised in the group. The bone samples were characterised by a well-vascularised compact

cortex with mostly longitudinal vascular canals. Few irregularly oriented canals could also be found. Osteocyte lacunae were large and very abundant. Haversian bone was recorded in *Toxodon*, *Nesodon*, and *Mesotherium*. This is a common feature in mammalian bone (Enlow & Brown, 1958), probably caused by increased loading in large-bodied species as discussed by Straehl et al. (2013) for xenarthrans. Areas of primary bone matrix were visible between secondary osteons, which displayed a mostly parallel-fibered to lamellar organisation. Localized areas of woven bone characterised by round osteocyte lacunae were also present. The most external layer of the cortex consisted of parallel-fibred bone with only very few secondary osteons and was in clear contrast to the heavily remodelled inner cortex. The study of Tomassini et al. (2015) on the palaeohistology of hemimandibles of *Paedotherium bonaerense* from the early Pliocene of Argentina discussed the processes affecting fossil remains before and after burial.

Pantodonta - Pantodonts are an extinct group of mammals that comprised large-bodied, heavily built omnivores and herbivores, from the Paleocene and Eocene of Laurasia. Only one study (Enlow and Brown 1958) examined the bone histology of this group. The rib of the Eocene pantodont *Coryphodon* showed primary lamellar bone with longitudinal vascularisation.

Laurasiatheria – Eulipotyphla - The comprehensive work of Enlow & Brown (1958) gave the first contribution on eulipotyphlan bone histology. They described the primary bone tissue of a *Talpa* tibia and a *Sorex* mandible as almost completely avascular lamellar bone. A juvenile humerus and radius showed in their outer cortex a “disorganised” (Enlow & Brown, (1958: p. 190) called it, being accompanied by oblique, radial, circumferential or longitudinal simple vascular canals. Klevezal (1996) discussed eulipotyphlan histology by emphasising growth marks (LAGs) in the bone cortex of mandibles and their value for skeletochronology.

Meier et al. (2013) studied the bone compactness of humeri of eleven extant and eight fossil talpid species and two non-talpid species. They could not detect any pattern of global compactness related to biomechanical specialization, phylogeny or size and concluded that at this small size the overall morphology of the humerus plays a predominant role in absorbing load. Morris (1970) evaluated the applicability of LAGs in extant hedgehog mandibles and found high correlation between age and LAG count.

In the giant galericine "hedgehog" *Deinogalerix* from the palaeoisland of Gargano (Table 1), Italy, the bone tissue at the inner layer of femur RGM.178017 and humerus RGM.425360 is characterised by parallel-fibred bone, whereas the outer layer and the trabecular bone is built by lamellar bone (Figs. 5A-C). In the bone cortex, simple longitudinal vascular canals and primary osteons are present. Primary bone tissue is partially replaced by irregularly shaped partly oblique secondary osteons. In the femur corresponding to an adult individual, five LAGs can be distinguished (Fig. 5C) indicating an individual age of minimum five years.

Chiroptera – Enlow & Brown (1958) described the primary bone tissue in chiropterans as lamellar bone surrounding a non-cancellous medullary cavity. Klevezal (1996) described the presence of LAGs in chiropteran bone tissue. Herdina et al. (2010) described the bone tissue of the baculum of three *Plecotus* species as lamellar bone surrounding a small medullary cavity similar to the arrangement of a Haversian system whereas the ends of the bone consisted of woven-fibred bone.

Perissodactyla – Enlow & Brown (1958), Sander & Andrassy (2006), Cuijpers (2006), and Hillier & Bell (2007) described long bones and ribs of fossil and extant equids as being primarily plexiform fibrolamellar with longitudinal vascular canals, accompanied by extensive remodelling including the occurrence of dense Haversian bone. Zedda et al. (2008) found a high

amount of Haversian tissue in extant horses and cattle. Osteons of the horse were more numerous and composed of a higher number of well-defined lamellae when compared to those of cattle. Diameter, perimeter and area of osteons and Haversian canals were always higher in horses than in cattle and this pattern was related to their different locomotor behaviour. Enlow and Brown (1958) additionally described a stratified, circumferential pattern of vascular canals in a mandible of a Miocene chalicothere (*Moropus*), i.e. laminar fibrolamellar bone tissue *sensu* Francillion-Vieillot et al. (1990). The authors demonstrated an identical pattern of bone tissues and vascular canals in several ribs of fossil tapirs from the Eocene. Sander & Andrassy (2006) described bone tissue of tibiae of Late Pleistocene woolly rhinocerotid (*Coelodonta antiquitatis*). They found predominantly laminar fibrolamellar bone as primary bone type besides a high amount of Haversian bone. Ricqlès, Taquet & Buffrénil (2009) described thin sections of several extant and extinct perissodactyls including chalicotheres, describing the distribution of primary and secondary bone as well as vascularisation. Cooper et al. (2014) considered anthracobunids as stem-perissodactyls, and concluded osteosclerosis in limb bones and ribs of anthracobunids to be consistent with the occupation of shallow-water habitats.

A rib of the giant rhinocerotoid *Paraceratherium* sp. (Fig. 1G, Table 1) from the Miocene of Turkey displays dense Haversian bone (Fig. 1I), whereas the bone cortex is heavily recrystallized and does not allow observations on primary bone.

Cetartiodactyla – Enlow & Brown (1958) gave a comprehensive overview on the bone histology of artiodactyls. The Miocene artiodactyls *Merycoidodon* and *Leptomeryx* showed in mandibles, maxillas, and ribs a reticular pattern of primary vascularisation next to secondary Haversian tissue. Extant taxa showed essentially plexiform fibrolamellar bone in long bones and reticular bone tissue in skull bones and mandibles. Singh (1974) studied the long bone tissue of a

mature specimen of the blue duiker *Cephalophus manticola*, and two perinatal specimens of the Indian sambar *Cervus unicolor* and the reindeer *Rangifer tarandus*. Whereas *Cephalophus* showed primary longitudinal vascularisation, the perinatal cervids revealed a reticular pattern of vascular canals. Plexiform fibrolamellar bone (Figs. 1B, 1C, 1E, 1F) was confirmed as primary bone tissue in artiodactyls in subsequent publications (Klevezal 1996; Horner, Ricqlès & Padian, 1999; Cuijpers, 2006; Sander & Andrassy, 2006; Hillier et al., 2007; Köhler et al., 2012; Marin-Moratalla, Jordana & Köhler, 2013; Kolb et al., 2015). Marin-Moratalla et al. (2014) identified the primary bone tissue in bovids as laminar. They studied 51 femora representing 27 ruminant species in order to determine the main intrinsic or extrinsic factors shaping the vascular and cellular network of fibrolamellar bone. Thus, the authors examined the correlation of certain life history traits in bovids, i.e. body mass at birth and adulthood as well as relative age at reproductive maturity. Quantification of vascular orientation and vascular and cell densities revealed that there is no correlation with broad climatic categories or life history. Instead, the authors found correlation with body mass since larger bovids showed more circular canals and lower cell densities than did smaller bovids. Mitchell and Sander (2014) suggested a three front model consisting of an apposition front, a Haversian substitution front, and a resorption front, and applied this model successfully to a humerus of red deer *Cervus elaphus*. They found moderate apposition and remodelling as well as slow resorption in the red deer specimen. Hofmann, Stein & Sander (2014) examined the lamina thickness in bone tissue (LD) in sauropodomorph dinosaurs and 17 mammalian taxa, including artiodactyls and perissodactyls. They found that LD is relatively constrained within the groups and that mean mammalian LD differs significantly from mean sauropodomorph LD. LD in suids was higher than in other mammals. The authors therefore concluded that laminar vascular architecture is most likely

determined by a combination of structural, functional as well as vascular supply and physiological causes.

For the present study, the bone cortex of one small (CKS 110/B), one intermediate (CKS 122/B), and one large juvenile (subadult; CKS 117) of the extinct Pleistocene dwarf hippopotamid of Cyprus, *Hippopotamus minor* (also called *Phanourios minor*, see van der Geer et al., 2010) were examined (Table 1). In the juvenile femora the bone tissue is characterised by reticular to plexiform fibrolamellar bone with an endosteal, inner circumferential layer consisting of lamellar bone (Fig. 6). The bone is generally highly vascularised with primary longitudinal vascular canals and primary osteons towards the outer part of the cortex. There are no Haversian systems in the small juvenile (Fig. 6B), although their content increases during ontogeny and is highest in the subadult specimen. Although heavily recrystallized, an adult tibia of *Hippopotamus minor* shows strong remodelling with partially dense Haversian bone occurring from the inner to the outermost part of the cortex. Towards the outer cortex of the subadult femur (Fig. 6D) and typically for large mammals, the amount of parallel-fibred bone within the fibrolamellar complex increases, indicating a decrease in growth rate.

Another taxon sampled for the current study is *Sinomegaceros yabei* (Table 1), which is, as *Megaloceros*, a large-sized megacerine deer. Although a thorough description is prevented by the suboptimal preservation of the specimens, some of their histological features can be given here. The primary bone of the inner cortex is highly vascularised, being formed by fibrolamellar tissue with a mostly plexiform vascularisation. The outer cortex is in turn weakly vascularised. The adult femur OMNH QV-4062 features seven LAGs (Fig. 7), with a 2.57 mm thick second growth zone, which is even greater than the extreme values found in the elk, *Alces* and *Megaloceros* (Kolb et al., 2015), and which indicates, as in the latter taxa, a high growth rate.

Several authors focused on the bone histology of cetaceans and sirenians for their peculiar aquatic lifestyle. Enlow & Brown (1958) described the primary bone tissue of skull bones and vertebrae of the porpoise (*Phocoena phocoena*) as featuring a reticular vascularisation with a high amount of remodelling including the occurrence of dense Haversian bone. Buffrénil and colleagues studied the microstructure of baleen whale bone tissue in several works. They found annually deposited well-defined LAGs in mandibular bone tissue of the common porpoise, *Phocoena phocoena* (Buffrénil, 1982). The humeral bone tissue of the common dolphin (*Delphinus delphis*) shows a cancellous texture without a free medullary cavity and more bone being eroded than deposited during ontogeny indicating an osteoporotic-like process (Buffrénil & Schoevaert, 1988). Buffrénil & Casinos (1995), by using standard microscopic methods, and Zylberberg et al. (1998), by using scanning and transmission electron microscopy, studied the rostrum of the extant Blainville's beaked whale *Mesoplodon densirostris*, demonstrating a high density because of hypermineralised tissue with longitudinal fibres in dense Haversian bone. Buffrénil, Dabin & Zylberberg (2004) demonstrated that the petro-tympanic bone complex in common dolphins consists of reticular to laminar fibrolamellar bone, initially being deposited as loose spongiosa with hypermineralised tissue and without Haversian remodelling. Two Eocene archaeocete taxa were shown to feature pachyostosis with hyperostosis (excessive bone growth) of the periosteal cortex very similar to the condition present in some sirenians (Buffrénil et al., 1990). The comparative study of Gray et al. (2007) analysed the ribs of ten specimens representing five extinct cetacean families from the Eocene as they make their transition from a terrestrial/semiaquatic to an obligate aquatic lifestyle over a 10-million-year period. The authors compared those data to nine genera of extant mammals, amongst them modern dolphins, and found profound changes of microstructure involving a shift in bone function. The mechanisms of

osteogenesis were flexible enough to accommodate the shift from a typical terrestrial form to osteosclerosis and pachyosteosclerosis, and then to osteoporosis in the first quarter of the evolutionary history of cetaceans. The limb bones and ribs of *Indohyus*, a taxon closely related to cetaceans, were shown to feature osteosclerosis, and considered as indicative of the use of bottom-walking as swimming mode (Thewissen et al., 2007; Cooper et al., 2012). Ricqlès, Taquet & Buffrénil (2009) published the description of a rediscovered collection of thin sections from the 19th century French palaeontologist Paul Gervais including sections of cetaceans. The most recent study on the bone microstructure of cetaceans is the one of Houssaye, Muizon & Gingerich (2015) analysing the bone microstructure of ribs and vertebrae of 15 archaeocete specimens, i.e. Remingtonocetidae, Protocetidae, and Basilosauridae using microtomography and virtual thin-sectioning (i.e. CT scanning). They found bone mass increase in ribs and femora, whereas vertebrae are essentially spongeous. Humeri changed from compact to spongeous whereas femora in basilosaurids became, for not being involved in locomotion, reduced, displaying strong osteosclerosis. The authors concluded that Remingtonocetidae and Protocetidae were probably shallow water swimmers, whereas basilosaurids, for their osseous specializations similar to those of modern cetaceans, are considered more active open-sea swimmers.

Creodonta – As it is the case for many other vertebrate taxa, Enlow and Brown (1958) are until today the only workers to have analysed the bone tissue of mammalian predators from the Paleogene and Early Neogene of North America, Africa, and Eurasia, the “creodonts”. Bone tissue of mandibles, ribs, and long bones has shown to consist of primary lamellar bone with longitudinal/radial vascularisation and secondary Haversian tissue, in general similar to the bone tissue found in modern carnivorans.

Carnivora – Enlow & Brown (1958) studied the mandible bone tissue of *Ursus* and found primary reticular bone and secondary dense Haversian bone, whereas a rib showed only dense Haversian bone. In the outer part, the bone cortex of *Ursus* consisted of plexiform bone. Chinsamy, Rich & Vickers-Rich (1998) found several LAGs in the zonal bone cortex of the polar bear. Hayashi et al. (2013) reported that the polar bear (*Urusus maritimus*) displays microanatomical features close to those of active swimmers in its limb bones, particularly in the humerus, and intermediate between aquatic and terrestrial taxa in the femur, despite its morphological features, which do not show particular adaptation for swimming. However, *U. maritimus* long bones still displayed a true medullary cavity. The authors suggested that this result, and notably the apparently stronger adaptation of the humerus for an aquatic mode of life, is probably linked to its swimming style because *U. maritimus* uses the forelimbs as the main propulsors during swimming.

Mephitis (skunk), *Procyon* (raccoon), *Mustela* (badger), *Felis* (cat), *Canis* (dog), and *Urocyon* (fox) all possess reticular and radial primary bone (Enlow & Brown 1958). However, the bone cortex of adult specimens in these taxa was dominated by secondary Haversian bone. The outer cortex of *Canis* was composed of primary plexiform bone tissue. The mongoose (*Herpestes*) showed in its femur primary longitudinal vascularised bone devoid of Haversian remodelling whereas the bone cortex of the American mink (*Neovison vison*) was composed of reticular and Haversian bone.

Singh (1974) found in felids and mustelids lamellar bone with radial to longitudinal vascularisation. Klevezal & Kleinenberg (1969) found annual LAGs in the bone cortex of carnivores. Several works dealt with the accuracy of LAGs in carnivores in comparison to dental histology as a tool of age determination: Johnston & Beauregard (1969) (*Vulpes*), Pascale &

Delattre (1981) (*Mustela*), King (1991) (*Mustela*), Klevezal (1996) (*Mustela*, *Martes*), Pascal & Castanet (1978) (*Felis*). The outcome was always in favour of dental cementum analysis. Buffrénil & Pascal (1984) concluded that in mink mandibles the deposition of LAGs is not strictly annual by using fluorescein and alizarin labelling.

The long bones of *Valenictus*, a Pliocene walrus (Odobenidae), were described as being osteosclerotic (Deméré, 1994).

Euarchontoglires – Rodentia – Early contributions on rodent bone histology were made by Enlow & Brown (1958) as well as Singh (1974). More recent ones are those of Klevezal (1996) on rest lines and age determination, Martiniakova et al. (2005) on rat bone histology, and Garcia-Martinez et al. (2011) on the bone histology of dormice. The bone tissue of rodents mainly consists of lamellar or parallel-fibred bone with longitudinal vascularisation as primary bone tissue. Development of Haversian bone is rare. Geiger et al. (2013) studied the bone cortex of a femur of the giant caviomorph *Phoberomys pattersoni* from the Miocene of Trinidad, and found it to be composed of lamellar-zonal bone. The specimen sampled showed alternating layers of compacted coarse cancellous bone and parallel-fibered primary bone with a reticulum-like structure. The authors reported Haversian tissue to be absent.

The femoral bone cortex of *Mikrotia magna*, a giant insular murine rodent from the Late Miocene former island of Gargano (Italy; Table 1), consists merely of compact bone. The bone matrix of the central part of the cortex is dominated by parallel-fibred bone with reticular vascularisation being pervaded by irregularly shaped and partially obliquely oriented secondary osteons (Figs. 8A-C), producing a distinct disorganised pattern (Enlow & Brown, 1958). The inner and outer parts of the cortex are formed by lamellar bone with poor longitudinal but mainly radial vascularisation. The thickness of those parts varies throughout the circumference of the

bone cortex and between samples. All the samples display LAGs. In the adult femur RGM.792085, four to five LAGs are counted. Resorption cavities are present close to the medullary cavity.

Thin sections of the femur of the dormouse *Leithia* sp. from the Pleistocene of Sicily (Table 1) are characterised by a compact cortex. The primary bone matrix is formed by lamellar bone pervaded by scarce and irregularly shaped and partially obliquely oriented secondary osteons (Figs. 8D-F). There is no LAG, suggesting a constant apposition rate. Large resorption cavities occur. The primary vascularisation is weak and limited to only few longitudinal to radial vascular canals.

Lagomorpha – For this study four different species of ochotonids (*Prolagus*) were investigated (Table 1). One mainland form (*Prolagus oeningensis* from La Grive France) and three island forms: The giant species *Prolagus sardus* (Sardinia, Italy) (Fig. 9A) and *P. imperialis* along with *P. apricenicus*, both from Gargano, Italy. Generally, the bone cortex of the femur and the humerus of *Prolagus* is compact. It is characterised by a bone matrix changing from parallel-fibered into lamellar bone from the central cortex towards the OCL (Figs. 9B-F). An endosteal lamellar layer is present. In most specimens the parallel-fibred bone is partly pervaded by irregularly shaped partially obliquely oriented secondary osteons, producing the "subendosteal layer of Haversian-like bone" *sensu* Pazzaglia et al. (2015: Fig. 6B). The primary bone cortex is in general weakly vascularised. Within the primary parallel-fibred bone, primary and simple longitudinal vascular canals as well as radial and reticular vascular canals occur and are arranged in an irregular manner. LAGs indicating minimum ages are present in some adult specimens. *Prolagus oeningensis* (Figs. 9B, 9C) gives a maximum count of three LAGs, *Prolagus apricenicus* a maximum count of two LAGs, and *Prolagus imperialis* as well as

Prolagus sardus each gives a maximum count of five LAGs (Figs. 9D-F). The femur of the juvenile *Prolagus sardus* (NMB Ty. 4974) is in the inner part of the cortex characterised by reticular vascularised fibrolamellar complex with a high amount of woven bone. Towards the bone surface, the amount of parallel-fibered bone is increasing and the vascularisation changes into longitudinal simple and primary vascular canals. In the area of the strongest curvature of the cortex, primary bone tissue is pervaded by obliquely oriented irregularly shaped secondary osteons. Our observations on lagomorph bone histology agree with Enlow and Brown's (1958) observations on *Lepus*. The same is the case for the study of Pazzaglia et al. (2015), who studied rabbit (*Oryctolagus cuniculus*) femora of different ontogenetic stages via micro CT-scanning. However, what they call laminar respectively plexiform bone tissue is not in agreement with the nomenclature of Francillon-Vieillot et al. (1990) used by us, i.e. longitudinal, radial, and reticular vascularisation.

Primates - Again, Enlow & Brown (1958) were the first to describe the bone tissue of extinct primates by sampling a mandible of the fossil Paleocene *Plesiolestes* and long bones of modern primates. The authors described primary bone tissue formed by lamellar bone. Vascularisation was mainly characterised by longitudinal primary vascular canals. Remodelling was partially abundant and the organisation of Haversian bone was in some areas of the bone cortex even dense. Those observations have been confirmed by the comparative studies of Cuijpers (2006) and Hillier & Bell (2007) as well as the conceptual ones of Bromage et al. (2009; see also above) and Castanet (2006; see also above). Castanet et al. (2004; see also above) found the inner and thicker part of the bone cortex of *Microcebus* long bones to be formed by parallel-fibred bone containing primary blood vessels and scarce primary osteons. In contrast, the outer part of the cortex is not vascularised. Crowder & Stout (2012) have compiled a book regarding the current

utilisation of histological analysis of bones and teeth within the field of anthropology, including the biology and growth of bone, histomorphological analysis, and age determination. There is extensive literature on hominoids, especially on bone pathologies in *Homo sapiens*, and in order not to go beyond the scope of this work, we cite here only some examples of publications in this area. Martinez-Maza, Rosas & García-Vargas (2006) and Martinez-Maza et al. (2011) analysed bone surfaces under the reflected light and scanning electron microscope in order to decipher modelling and remodelling patterns in extant hominine facial skeletons and mandibles as well as in Neanderthal mandibles, explaining specific morphological traits. Schultz and Schmidt-Schultz (2014) examined fossil human bone and reviewed the methods and techniques of light microscopy, scanning electron microscopy, and advantages of polarisation microscopy for palaeoanthropology. In this context it is noteworthy that estimation of individual age in anthropology is carried out by mainly two methods (Schultz & Schmidt-Schultz, 2014): (1) the histomorphometric method (HMM) and (2) the histomorphologic method (HML). The HMM method is applied mainly to long bones (e.g. Kerley, 1965; Drusini, 1987) and is based upon the frequencies of osteons (Haversian systems), fragmented osteons (interstitial lamellae), non-Haversian canals, and the percentage of the external circumferential lamellae. The HML method is based upon the morphology (presence, size, shape, development) of external and internal circumferential lamellae, osteons, fragmented osteons, and non-Haversian canals (e.g. Schultz, 1997). Skinner et al. (2015) studied pattern of trabeculae distribution of metacarpals in *Australopithecus africanus* and Pleistocene hominins. They found a 'human-like' pattern, considered as consistent with tool use. Ryan & Shaw (2015) quantified the proximal femur trabecular bone structure using micro-CT data from 31 extant primate taxa (229 individuals) and four distinct archaeological human populations (59 individuals) representing sedentary

agriculturalists and mobile foragers. Trabecular bone variables indicate that the forager populations had significantly higher bone volume fraction, thicker trabeculae, and lower relative bone surface area compared with the two agriculturalist groups. The authors did not find any significant differences between agriculturalist and forager populations for trabecular spacing, number, or degree of anisotropy. Ryan & Shaw concluded in revealing a correspondence between human behaviour and bone structure in the proximal femur, indicating that more highly mobile human populations have trabecular bone structure similar to what would be expected for wild non-human primates of the same body mass, thus emphasising the importance of physical activity and exercise for bone health and the attenuation of age-related bone loss.

Selected contributions on mammalian histology

In the following part, selected contributions on mammalian histology are separately discussed, since they deserve a more detailed evaluation in our view because they address special aspects and/or applications of palaeohistological work. Enlow's & Brown's (1958) outstanding comparative work on mammalian bone histology is not further mentioned in this section, since it is repeatedly discussed above.

Klevezal & Kleinenberg (1969) were the first to recognise the presence and importance of rest lines in the bone cortex of mammals for skeletochronological studies (see also Chinsamy-Turan, 2005). In their work, which was originally published in Russian in 1967, they found that in mammals, unlike the zonal bone forming in reptiles, the recording part including LAGs is the outer or periosteal zone (see also above). Klevezal (1996) found that not in every mammalian taxon rest lines are formed from the first year of life. Therefore she suggested a variable correction factor for different mammalian taxa, and concluded that the best structures for

recording growth and age are dentine and especially cementum (Klevezal, 1996). In her detailed and comprehensive study of recording structures in mammals, she found that the growth rate of a particular structure can change according to the growth rate of the whole organism and that seasonal changes of growth intensity of an animal as a whole determine the formation of growth layers. Klevezal (1996) argued that changes in humidity, not temperature, may play a role as seasonal factor in growth.

Dumont et al. (2013) documented the microstructure of vertebral centra using 2D histomorphometric analyses of vertebral centra of 98 therian mammal species that cover the main size ranges and locomotor adaptations known in therian taxa. The authors extracted eleven variables relative to the development and geometry of trabecular networks from CT scan mid-sagittal sections. Random taxon reshuffling and squared change parsimony indicated a phylogenetic signal in most of the variables. Furthermore, based on those variables, it was possible to discriminate three categories of locomotion among the sampled taxa: a) terrestrial + flying + digging + amphibious forms, b) coastal oscillatory aquatic taxa, and c) pelagic oscillatory aquatic forms represented by oceanic cetaceans. Dumont and colleagues concluded that, when specific size increases, the length of trabecular networks, as well as trabecular proliferation, increase with positive allometry. They found that, by using six structural variables, locomotion mode can be predicted with a 97.4% success rate for terrestrial forms, 66.7% for coastal oscillatory, and 81.3% for pelagic oscillatory.

Sander & Andrassy (2006) described the occurrence of LAGs in 21 long bones (mainly tibiae and metatarsals) of herbivorous mammals from the Late Pleistocene of Germany comprising the extinct giant deer *Megaloceros giganteus*, the red deer *Cervus elaphus*, the reindeer *Rangifer tarandus*, the extinct bovids *Bos primigenius* and *Bison priscus*, the equid

Equus sp., the extinct rhinocerotid *Coelodonta antiquitatis*, and the extinct elephantid *Mammuthus primigenius*. All samples showed fibrolamellar bone and a varying degree of remodelling and most of the long bones displayed LAGs. Because of the frequent find of LAGs in endothermic animals the authors questioned the argument that LAGs in dinosaur bone indicate ectothermy.

Köhler & Moyà-Solà (2009) examined the long-bone histology of *Myotragus*, a Plio-Pleistocene bovid from the Balearic Islands. It revealed lamellar-zonal tissue throughout the cortex, a trait exclusive to ectothermic reptiles. According to Köhler and colleagues, *Myotragus* grew unlike any other mammal but similar to crocodiles at slow and flexible rates, ceased growth periodically, and attained somatic maturity late by 12 years. The authors concluded that this developmental pattern indicates that *Myotragus*, much like extant reptiles, synchronized its metabolic requirements with fluctuating resource levels.

Kolb et al. (2015) performed a histological analysis of long bones and teeth representing eleven extinct and extant cervid taxa, amongst them the dwarf island morphotypes of *Candiacervus* from the Late Pleistocene of Crete and the giant deer *Megaloceros giganteus*, both in a clade together with fallow deer (*Dama dama*) among extant species. Bone tissue types observed have been similar, indicating a comparable mode of growth across the eight species examined, with long bones mainly possessing primary plexiform fibrolamellar bone (Figs. 1B, 1C, 1E, 1F). Dwarf *Candiacervus* have been characterised by low growth rates, *Megaloceros* by high rates, and the lowest recorded rates were those of the Miocene small stem cervid *Procervulus praelucidus*. It can be noted that *Sinomegaceros yabei*, sampled for the present study, features a very thick second growth zone, which suggests a high growth rate, comparable to that of the closely related *Megaloceros*. Skeletal maturity estimates (see also above) indicated

late attainment in sampled *Candiacervus* and *Procervulus*. Tooth cementum analysis of first molars of two senile *Megaloceros giganteus* specimens revealed ages of 16 and 19 years whereas two old dwarf *Candiacervus* specimens gave ages of 12 and 18 years. Kolb et al. (2015) concluded that the bone histological condition found in *Candiacervus* has features in common with that of *Myotragus* (Köhler & Moyà-Solà, 2009), but is achieved with a lesser modification of bone tissue and suggested various modes of life history and size evolution among island mammals.

Discussion and conclusions

A large variety of bone tissues and vascularisation patterns is encountered in mammalian bone reaching from lamellar or parallel-fibred to fibrolamellar or woven-fibred bone, highly depending on taxon and individual age. A plexiform to laminar organisation of vascular canals within fibrolamellar bone is typically found in taxa containing large-bodied species such as non-mammalian synapsids, laurasiatherians, and afrotherians. The deposition of Haversian systems throughout ontogeny of synapsids is common, only in rodents their content is usually low. Table 2 gives a summary on general patterns of bone histological features encountered in major synapsid clades.

Histology of island mammals – Three juvenile specimens of the dwarf island hippopotamid *Hippopotamus minor* from the Late Pleistocene of Cyprus show reticular to plexiform fibrolamellar bone, which does not indicate an island-specific pattern of bone growth or life history but a mode of growth similar to continental hippopotamid relatives instead. The bone cortex of the dormouse *Leithia* sp. from the Pleistocene of Sicily is characterised by lamellar bone and low vascularisation. *Mikrotia magna*, the giant island rodent from the Late

Miocene of Gargano, Italy shows in the central part of the cortex parallel-fibred bone with reticular vascularisation being pervaded by irregularly shaped and partially obliquely oriented secondary osteons, whereas the inner and outer parts of the cortex are formed by lamellar bone. Three fossil species of insular giant *Prolagus* and the fossil continental lagomorph *Prolagus oeningensis* exhibit in their bone cortex mainly parallel-fibred bone and reticular, radial as well as longitudinal vascularisation thus indicating similarity of bone histological arrangements in continental and island species of rodents and lagomorphs. The highest minimum age found in *Prolagus sardus* and *P. imperialis* of five years are well within the known longevities of extant ochotonids such as *Ochotona princeps* (seven years in captivity) and *O. hyperborean* (9.4 years in captivity) (Tacutu et al., 2013). A minimal individual age deduced from growth marks in the bone tissue of *Deinogalerix* specimen RGM 178017 lies also well within the known longevities for extant erinaceids such as *Erinaceus europaeus* (11.7 years in captivity), *E. concolor* (seven years in captivity), and *E. amurensis* (9.4 years in captivity) whereas longevity data for extant galericines are not yet available (Tacutu et al., 2013).

The insular bovid *Myotragus* dwelt on Majora for 5.2 Ma (Köhler & Moyà-Solà, 2009) and therefore likely much longer than the insular forms examined in this study (van der Geer et al., 2010). A high degree of bone histological and life history modification as described by Köhler & Moyà-Solà (2009) for *Myotragus* in comparison to continental artiodactyls could not be confirmed for the insular species of this study. The absence of modification of bone tissue and longevity in insular lagomorphs, rodents, insectivores, and hippopotamids could be related to shorter persistence times and different island size (Lomolino et al., 2012; Lomolino et al., 2013; Kolb et al., 2015)., in line with Austad & Fischer (1991), McNab (1994; 2002; 2010), Raia,

Barbera & Conte (2003), Curtin et al. (2012), and Kolb et al. (2015). We therefore suggest the presence of various modes of mammalian life history evolution on islands.

Future research fields

New technologies - 3D reconstructions attained by virtual image analysis gain increasing importance for palaeontological research at the anatomical, microanatomical, and even histological levels (Sanchez et al., 2012; Clément & Geffard-Kuriyama, 2010; Curtin et al., 2012; see also Ricqlès, 2011). The potential advantages of virtual imaging as a method are obvious: First, specimens do not have to be damaged for invasive sampling. Second, a third dimension, usually gained by time consuming serial sectioning or preparation of orthogonally oriented thin sections, is easily available. Third, virtual imaging techniques allow continuous "zooming" from the histological to the micro- and macronatomical levels of structural organisation. High resolution synchrotron virtual histology provides new 3D insights into the submicron-scale histology of fossil and extant bones. This is based on the development of new data acquisition strategies, pink-beam configurations, and improved processing tools (Sanchez et al., 2012). Nevertheless, for the high resolution optical properties of a polarisation microscope and their applications for identification and analysis of bone microstructure and as well for the comparatively low amount of financial resources needed, traditional thin sections are far from being completely replaced by virtual imaging techniques. Moreover, new statistical methods allow extraction of phylogenetic signals from bone microstructure and of high specimen numbers (Laurin, 2004; Laurin, Girondot & Loth, 2004; Cubo et al., 2008). High performance computers additionally sustain attainment of ecological, biomechanical, and phylogenetic signals (Cubo et al., 2005; Cubo et al., 2008; Laurin, Girondot & Loth, 2004; Laurin et al., 2004; Ricqlès & Cubo,

2010; Hayashi et al., 2013) taking into account the variability of bone tissues produced by multiple factors. The creation of histological databases will soon be necessary due to an increasing number of palaeohistological publications and growing collections of thin sections (Ricqlès, Castanet & Francillon-Vieillot, 2004; Ricqlès, Taquet & Buffrénil, 2009; Bromage, 2006; Kriloff et al., 2008; Scheyer, 2009-2015; Canoville & Laurin, 2010; O'Leary & Kaufmann, 2012).

Extant vertebrate biology - Actualistic models are essential for the interpretation of fossil hard tissues in every sense, no matter if developmental and life historical, histophysiological, morphological, ecological, or systematic. Living animals present the basis for inferring palaeobiological conclusions and this has already been done in several bone histological works (e.g. Canoville & Laurin, 2010; Köhler et al., 2012, Marin-Moratalla, Jordana & Köhler, 2013; Marin-Moratalla et al., 2014; Kolb et al. 2015).

Especially in regard of deciphering life history signals, the actualistic approach is and will become increasingly fundamental (e.g. Köhler & Moyà-Solà, 2009; Köhler et al., 2012; Marin-Moratalla, Jordana & Köhler, 2013; Marin-Moratalla et al., 2014; Kolb et al., 2015). Life history variables such as annual growth rate, somatic/sexual maturity, and longevity and their signal in bone microstructure help to understand the palaeobiology not only of fossil mammals but tetrapods in general. It is possible using bone histology to quantify growth rates and vascularisation or cellular density in mammals as a relative proxy for growth rate (Curtin et al., 2012; Kolb et al., 2015; Marin-Moratalla, Jordana & Köhler, 2013), whereby the existing literature on the paleobiology of dinosaurs has been used as a starting point. However, not every methodological approach used for dinosaurs is applicable or relevant for mammals (e.g.

Erickson, Curry Rogers & Yerby, 2001; Griebeler, Klein & Sander, 2013; Kolb et al., 2015). No one stated it better than Armand de Ricqlès: „The possibilities of using bone histology of extant vertebrates for various fundamental or applied research, whether on life history traits, ecology, or microevolution, are simply boundless.“ (Ricqlès, 2011).

Acknowledgments

We thank Naturalis Biodiversity Center, Leiden, the Netherlands, Loïc Costeur (Naturhistorisches Museum Basel, Switzerland), George Lyras (Museum of Paleontology and Geology, University of Athens, Greece), Nigel Monaghan (National Museum of Ireland, Natural History), Hiroyuki Taruno (Osaka Museum of Natural History, Japan), Frank Zachos and Alexander Bibl (Naturhistorisches Museum Wien, Austria), Pierre-Olivier Antoine (Institut des Sciences de l'Evolution-Montpellier, France), and Ebru Albayrak, (MTA Natural History Museum, The General Directorate of Mineral Research and Exploration, Ankara, Turkey) for organising and/or providing specimens for histological study. Alexandra Wegmann and Fiona Straehl are thanked for help with bone histological preparation, and Madeleine Geiger for fruitful discussions (all Palaeontological Institute of the University of Zurich, Switzerland).

References

Aeby C. 1878. Das histologische Verhalten fossilen Knochen- und Zahngewebes. *Archiv für Mikroskopische Anatomie* 15:371-382.

Agustí J, and Antón M. 2002. *Mammoths, sabertooths and hominids*. New York: Columbia University Press.

Amprino R. 1947. La structure du tissu osseux envisagee comme l'expression de différences dans la vitesse de l'accroissement. *Archives de Biologie* 58:315-330.

Amson E, Muizon C de, Laurin M, Argot C, and Buffrénil V de. 2014. Gradual adaptation of bone structure to aquatic lifestyle in extinct sloths from Peru. *Proceedings of the Royal Society B* 281:1-6.

Amson E, Muizon C de, Domning DP, Argot C, and Buffrénil V de. 2015. Bone histology as a clue for resolving the puzzle of a dugong rib in the Pisco Formation, Peru. *Journal of Vertebrate Paleontology*: e922981.

Austad SN, and Fischer KE. 1991. Mammalian aging, metabolism, and ecology: Evidence from the bats and marsupials. *Journal of Gerontology* 46:B47-53.

Bennett AF, and Ruben AJ. 1986. The metabolic and thermoregulatory status of therapsids. In: Hotton N, MacLean PD, Roth JJ, and Roth EC, eds. *The ecology and biology of mammal-like reptils*. Washington: Smithsonian Institution Press, 207-218.

Benson RBJ. 2012. The global interrelationships of basal synapsids: cranial and postcranial morphological partitions suggest different topologies. *Journal of Systematic Palaeontology* 10:601-624.

Boef M de, and Larsson HCE. 2007. Bone microstructure: quantifying bone vascular orientation. *Canadian Journal of Zoology* 85:63-70.

Botha J, and Chinsamy A. 2000. Growth patterns deduced from the bone histology of the cynodonts *Diademodon* and *Cynognathus*. *Journal of Vertebrate Paleontology* 20:705-711.

Botha J, and Chinsamy A. 2004. Growth and life habits of the Triassic cynodont *Trirachodon*, inferred from bone histology. *Acta Palaeontologica Polonica* 49:619-627.

Botha J, and Chinsamy A. 2005. Growth patterns of *Thrinaxodon liorhinus*, a non-mammalian cynodont from the Lower Triassic of South Africa. *Palaeontology* 48:385-394.

Botha-Brink J, Abdala F, and Chinsamy A. 2012. The radiation and osteohistology of nonmammaliaform cynodonts. In: Chinsamy-Turan A, ed. *Forerunners of mammals: radiation, histology, biology*. Bloomington: Indiana University Press, 223-246.

Botha-Brink J, and Angielczyk KD. 2010. Do extraordinarily high growth rates in Permo-Triassic dicynodonts (Therapsida, Anomodontia) explain their success before and after the end-Permian extinction? *Zoological Journal of the Linnean Society* 160:341-365.

Brink KS, and Reisz RR. 2014. Hidden dental diversity in the oldest terrestrial apex predator *Dimetrodon*. *Nature Communications* 5:3269.

Bromage TG. 2006. Donald H. Enlow Digital Image Library. *Available at http://www.nyu.edu/dental/enlow/* (accessed 13 May 2015).

Bromage TG, Lacruz RS, Hogg R, Goldman HM, McFarlin SC, Warshaw J, Dirks W, Perez-Ochoa A, Smolyar I, Enlow DH, and Boyde A. 2009. Lamellar bone is an incremental tissue reconciling enamel rhythms, body size, and organismal life history. *Calcified Tissue International* 84:388-404.

Buffrénil V de. 1982. Données préliminaires sur la présence de lignes d'arret de croissance périostiques dans la mandibule du marsouin commun, *Phocoena phocoena* (L.), et leur utilisation comme indicateur de I'age. *Canadian Journal of Zoology* 60:2557-2567.

Buffrénil V de, Astibia H, Pereda Suberbiola X, and Berreteaga A. 2008. Variation in bone histology of middle Eocene sirenians from western Europe. *Geodiversitas* 30:425-432.

Buffrénil V de, Canoville A, D'Anastasio R, and Domning DP. 2010. Evolution of sirenian pachyosteosclerosis, a model-case for the study of bone structure in aquatic tetrapods. *Journal of Mammalian Evolution* 17:101–120.

Buffrénil V de, and Casinos A. 1995. Observations histologiques sur le rostre de *Mesoplodon densirostris* (Mammalia, Cetacea, Ziphiidae): le tissu osseux le plus dense connu. *Annales des Sciences Naturelles, Zoologie, Paris, 13e Série* 16:21-36.

Buffrénil V de, and Castanet J. 2000. Reptiles age estimation by skeletochronology in the Nile Monitor (*Varanus niloticus*), a highly exploited species. *Journal of Herpetology* 34:414-424.

Buffrénil V de, Dabin W, and Zylberberg L. 2004. Histology and growth of the cetacean petro-tympanic bone complex. *Journal of Zoology* 262:371-381.

Buffrénil V de, and Pascal B. 1984. Croissance et morphogenèse postnatales de la mandibule du vison (*Mustela vison*, Schreiber): données sur la dynamique et l'interprétation fonctionnelle des dépots osseux mandibulaires. *Canadian Journal of Zoology* 62:2026-2037.

Buffrénil V de, Ricqlès Ad, Ray CE, and Domning DP. 1990. Bone histology of the ribs of the archaeocetes (Mammalia: Cetacea). *Journal of Vertebrate Paleontology* 10:455-466.

Buffrénil V de, and Schoevaert D. 1988. On how the periosteal bone of the delphinid humerus becomes cancellous: ontogeny of a histological specialization. *Journal of Morphology* 198:149-164.

Bybee PJ, Lee AH, and Lamm ET. 2006. Sizing the Jurassic theropod dinosaur *Allosaurus*: assessing growth strategy and evolution of ontogenetic scaling of limbs. *Journal of Morphology* 267:347-359.

Canoville A, and Laurin M. 2010. Evolution of humeral microanatomy and lifestyle in amniotes, and some comments on palaeobiological inferences. *Biological Journal of the Linnean Society* 100:384-406.

Castanet J. 1994. Age estimation and longevity in reptiles. *Gerontology* 40:174-192.

Castanet J. 2006. Time recording in bone microstructures of endothermic animals; functional relationships. *Comptes Rendus Palevol* 5:629-636.

Castanet J, and Baez M. 1991. Adaptation and evolution in Gallotia lizards from the Canary Islands: age, growth, maturity and longevity. *Amphibia-Reptilia* 12:81-102.

Castanet J, Croci S, Aujard F, Perret M, Cubo J, and de Margerie E. 2004. Lines of arrested growth in bone and age estimation in a small primate: *Microcebus murinus*. *Journal of Zoology* 263:31-39.

Castanet J, Curry Rogers KA, Cubo J, and Boisard J-J. 2000. Periosteal bone growth rates in extant ratites (ostriche and emu). Implications for assessing growth in dinosaurs. *Comptes Rendus de l'Academie des sciences, Series III, Sciences de la Vie* 323:543-550.

Castanet J, and Smirina EM. 1990. Introduction to the skeletochronological method in amphibians and reptiles. *Annales des sciences naturelles, Zoologie* 11:191-196.

Chávez-Aponte EO, Alfonzo-Hernández I, Finol HJ, Barrios N. CE, Boada-Sucre A, and Carrillo-Briceño JD. 2008. Histologia y ultraestructura de los osteodermos fosiles de *Glyptodon clavipes* y *Holmesina* sp. (Xenarthra: Cingulata). *Interciencia* 33:616-619.

Chinsamy A, and Abdala F. 2008. Palaeobiological implications of the bone microstructure of South American traversodontids (Therapsida: Cynodontia). *South African Journal of Science* 104:225-230.

Chinsamy A, and Hurum JH. 2006. Bone microstructure and growth patterns of early mammals. *Acta Palaeontologica Polonica* 51:325-338.

Chinsamy A, Rich T, and Vickers-Rich P. 1998. Polar dinosaur bone histology. *Journal of Vertebrate Paleontology* 18:385-390.

Chinsamy A, and Rubidge BS. 1993. Dicynodont (Therapsida) bone histology: phylogenetic and physiological implications. *Palaeontologia africana* 30:97-102.

Chinsamy-Turan A. 2005. *The microstructure of dinosaur bone: Deciphering biology with fine scale techniques*. Baltimore: Johns Hopkins University Press.

Chinsamy-Turan A. 2012a. Forerunners of mammals: radiation, histology, biology. Life of the past. Bloomington: Indiana University Press. p 352.

Chinsamy-Turan A. 2012b. Microstructure of bones and teeth of nonmammalian therapsids. In: Chinsamy-Turan A, ed. *Forerunners of mammals: radiation, histology, biology*. Bloomington: Indiana University Press, 65-88.

Clément G, and Geffard-Kuriyama D. 2010. Imaging and 3D in palaeontology and palaeoanthropology. *Comptes Rendus Palevol* 9:259–264.

Cook SF, Brooks ST, and Ezra-Cohn HE. 1962. Histological studies on fossil bone. *Journal of Paleontology* 36:483-494.

Cooper LN, Seiffert ER, Clementz M, Madar SI, Bajpai S, Hussain ST, and Thewissen JGM. 2014. Anthracobunids from the middle eocene of India and pakistan are stem perissodactyls. *PloS one* 9:e109232.

Cooper LN, Thewissen JGM, S. Bajpai S, and Tiwari BN. 2012. Postcranial morphology and locomotion of the Eocene raoellid *Indohyus* (Artiodactyla: Mammalia). *Historical Biology* 24:279-310.

Cormack D. H. 1987. *Ham's histology*. Philadelphia: J. B. Lippincott Company.

Crowder C, and Stout S. 2012. *Bone histology: an anthropological perspective*. Boca Raton: CRC Press.

Cubo J, Legendre P, Ricqlès A de, Montes L, Margerie E de, Castanet J, and Desdevise Y. 2008. Phylogenetic, functional and structural components of variation in bone growth rate in amniots. *Evolution and Development* 10:217-227.

Cubo J, Ponton F, Laurin M, Margerie E de, and Castanet J. 2005. Phylogenetic signal in bone microstructure of sauropsids. *Systematic Biology* 54:562–574.

Cuijpers A. 2006. Histological identification of bone fragments in archaeology: telling humans apart from horses and cattle. *International Journal of Osteoarchaeology* 16 465–480.

Curtin AJ, Macdowell AA, Schaible EG, and Roth L. 2012. Noninvasive histological comparison of bone growth patterns among fossil and extant neonatal elephantids using synchrotron radiation X-ray microtomography. *Journal of Vertebrate Paleontology* 32:939-955.

Da Costa Pereira PVLG, Victer GD, Porpino KDO, and Bergqvist LP. 2012. Osteoderm histology of Late Pleistocene cingulates from the intertropical region of Brazil. *Acta Palaeontologica Polonica* 59:543-552.

Deméré TA. 1994. Two new species of fossil walruses (Pinnipedia: Odobenidae) from the upper Pliocene San Diego Formation, California. *Proceedings of the San Diego Society of Natural History* 29:77-98.

Drusini AZ. 1987. Refinement of two methods for the histomorphometric determination of age in human bone. *Zeitschrift für Morphologie und Anthropologie* 77:167-176.

Dumont M, Laurin M, Jacques F, Pellé E, Dabin W, and Buffrénil V de. 2013. Inner architecture of vertebral centra in terrestrial and aquatic mammals: a two-dimensional comparative study. *Journal of Morphology* 274:570-584.

Enlow DH. 1962. A study of the postnatal growth and remodeling of bone. *American Journal of Anatomy* 110:79-101.

Enlow DH. 1969. The bone of reptiles. In: Gans C, Bellairs AdA, and Parsons TS, eds. *Biology of the Reptilia Vol 1 Morphology A*: Academic Press, London, 45-80.

Enlow DH, and Brown SO. 1957. A comparative histological study of fossil and recent bone tissues. Part II. *Texas Journal of science* 9:186-214.

Enlow DH, and Brown SO. 1958. A comparative histological study of fossil and recent bone tissues. Part III. *Texas Journal of science* 10:187-230.

Erickson GM. 2014. On dinosaur growth. *Annual Review of Earth and Planetary Sciences* 42:675-697.

Erickson GM, Curry Rogers K, and Yerby SA. 2001. Dinosaurian growth patterns and rapid avian growth rates. *Nature* 412:429-433.

Erickson GM, Makovicky PJ, Currie PJ, Norell MA, Yerby SA, and Brochu CA. 2004. Gigantism and comparative life-history parameters of tyrannosaurid dinosaurs. *Nature* 430:772-775.

Ezra HC, and Cook SF. 1959. Histology of mammoth bone. *Science* 129 465–466.

Forasiepi AM, Cerdeño E, Bond M, Schmidt GI, Naipauer M, Straehl FR, Martinelli AG, Garrido AC, Schmitz MD, and Crowley JL. 2014. New toxodontid (Notoungulata) from the Early Miocene of Mendoza, Argentina. *Paläontologische Zeitschrift* DOI 10.1007/s12542-014-0233-5.

Francillon-Vieillot H, Buffrénil V de, Castanet J, Géraudie J, Meunier FJ, Sire JY, and Ricqlès A de. 1990. Microstructure and mineralization of vertebrate skeletal tissues. In: Carter JG, editor. Skeletal Biomineralization: Patterns, Processes and Evolutionary Trends. New York: Van Nostrand Reinhold. p 471–530.

Frylestam B, and von Schantz T. 1977. Age determination of European hares based on periosteal growth lines. *Mammal Review* 7:151-154.

Garcia-Martinez R, Marin-Moratalla N, Jordana X, and Köhler M. 2011. The ontogeny of bone growth in two species of dormice: Reconstructing life history traits. *Comptes Rendus Palevol* 10:489-498.

Geiger M, Wilson LAB, Costeur L, Sánchez R, and Sánchez-Villagra MR. 2013. Diversity and body size in giant caviomorphs (Rodentia) from the Northern Neotropics—study of femoral variation. *Journal of Vertebrate Paleontology* 33:1449-1456.

Germain D, and Laurin M. 2005. Microanatomy of the radius and lifestyle in amniotes (Vertebrata, Tetrapoda). *Zoologica Scripta* 34:335-350.

Gray NM, Kainec K, Madar S, Tomko L, and Wolfe S. 2007. Sink or Swim? Bone density as a mechanism for buoyancy control in early cetaceans. *Anatomical Record* 290:638-653.

Green JL, M. H. Schweitzer MH, and Lamm E-T. 2010. Limb bone histology and growth in *Placerias hesternus* (Therapsida: Anomodontia) from the Upper Triassic of North America. *Palaeontology* 53:347-364.

Griebeler EM, Klein N, and Sander PM. 2013. Aging, maturation and growth of sauropodomorph dinosaurs as deduced from growth curves using long bone histological data: an assessment of methodological constraints and solutions. *PloS one* 8: e67012.

Gross W. 1934. Die Typen des mikroskopischen Knochenbaues bei fossilen Stegocephalen und Reptilien. *Zeitschrift für Anatomie und Enwicklungsgeschichte* 103:731-764.

Habermehl K-H. 1985. *Altersbestimmung bei Wild- und Pelztieren - Möglichkeiten und Methoden - Ein praktischer Leitfaden für Jäger, Biologen und Tierärzte*. Hamburg, Berlin: Verlag Paul Parey.

Hayashi S, Houssaye A, Nakajima Y, Chiba K, Ando T, Sawamura H, Inuzuka N, Kaneko N, and Osaki T. 2013. Bone inner structure suggests increasing aquatic adaptations in Desmostylia (Mammalia, Afrotheria). *PloS one* 8:e59146.

Herdina AN, Herzig-Straschil B, Hilgers H, Metscher BD, and Plenk HJ. 2010. Histomorphology of the penis bone (baculum) in the gray long-eared bat *Pleocotus austriacus* (Chiroptera, Vespertilionidae). *The Anatomical Record* 293:1248–1258.

Hill RV. 2006. Comparative anatomy and histology of xenarthran osteoderms. *Journal of Morphology* 267:1441-1460.

Hillier ML, and Bell LS. 2007. Differentiating human bone from animal bone: A review of histological methods. *Journal of Forensic Sciences* 52:249−263.

Hillier ML, and Bell LS. 2007. Differentiating human bone from animal bone: a review of histological methods. *Journal of Forensic Sciences* 52:249−263.

Hofmann R, Stein K, and Sander PM. 2014. Constraints on the lamina density of laminar bone architecture of large-bodied dinosaurs and mammals. *Acta Palaeontologica Polonica* 59 287-294.

Horner JR, Ricqlès A de, and Padian K. 1999. Variation in dinosaur skeletochronology indicators: implications for age assessment and physiology. *Paleobiology* 25:295-304.

Horner JR, Ricqlès A de, and Padian K. 2000. Long bone histology of the hadrosaurid dinosaur *Maiasaura peeblesorum*: growth dynamics and physiology based on an ontogenetic series of skeletal elements. *Journal of Vertebrate Paleontology* 20:115-129.

Horner JR, and Padian K. 2004. Age and growth dynamics of *Tyrannosaurus rex*. *Proceedings of the Royal Society of London B* 271:1875-1880.

Houssaye A, P. T, Muizon C de, and Gingerich PD. 2015. Transition of Eocene whales from land to sea: evidence from bone microstructure. *PloS one* 10:e0118409.

Huttenlocker AK. 2008. Comparative osteohistology of hyperelongate neural spines in basal synapsids (Vertebrata: Amniota): Growth and mechanical considerations MSc MSc thesis. California State University.

Huttenlocker AK, and Botha-Brink J. 2013. Body size and growth patterns in the therocephalian *Moschorhinus kitchingi* (Therapsida: Eutheriodontia) before and after the end-Permian extinction in South Africa. *Paleobiology* 39:253–277.

Huttenlocker AK, and Botha-Brink J. 2014. Bone microstructure and the evolution of growth patterns in Permo-Triassic therocephalians (Amniota, Therapsida) of South Africa. *PeerJ* 2:e325:1-31.

Huttenlocker AK, Mazierski D, and Reisz RR. 2011. Comparative osteohistology of hyperelongate neural spines in the Edaphosauridae (Amniota: Synapsida). *Palaeontology* 54:573-590.

Huttenlocker AK, and Rega E. 2012. The paleobiology and bone microstructure of pelycosaurian-grade synapsids. In: Chinsamy-Turan A, ed. *Forerunners of mammals: radiation, histology, biology*. Bloomington: Indiana University Press, 91-119.

Huttenlocker AK, Rega E, and Sumida SS. 2010. Comparative anatomy and osteohistology of hyperelongate neural spines in the sphenacodontids *Sphenacodon* and *Dimetrodon* (Amniota: Synapsida). *Journal of Morphology* 271:1407-1421.

Huttenlocker AK, Woodward HN, and Hall BK. 2013. The biology of bone. In: Padian K, and Lamm E-T, eds. *Histology of fossil tetrapods - Advancing methods, analysis and interpretation*. Berkeley, Los Angeles, London: University of California Press, 13-34.

Jasinoski SC, Rayfield EJ, and Chinsamy A. 2010a. Functional implications of dicynodont cranial suture morphology. *Journal of Morphology* 271:705-728.

Jasinoski SC, Rayfield EJ, and Chinsamy A. 2010b. Mechanics of the scarf premaxilla-nasal suture in the snout of *Lystrosaurus*. *Journal of Vertebrate Paleontology* 30:1283-1288.

Johnston DH, and Beauregard M. 1969. Rabies epidemiology in Ontario. *Bulletin of the Wildlife Disease Association* 5:357-370.

Kaiser HE. 1960. Untersuchungen zur vergleichenden Osteologie der fossilen und rezenten Pachyostosen. *Palaeontographica Abteilung A* 114:113-196.

Kerley ER. 1965. The microscopic determination of age in human bone. *American Journal of Physical Anthropology* 23:149–163.

Kielan−Jaworowska Z, Cifelli RL, and Luo XZ. 2004. *Mammals from the age of dinosaurs: origins, evolution, and structure*. New York: Columbia University Press.

King CM. 1991. A review of age determination methods for the stoat *Mustela erminea*. *Mammal Review* 21:31-49.

Kiprijanoff W. 1883. Studien über die fossilien Reptilien Russlands. IV. Theil. Ordnung Grocodilina Oppel. *Mémoires de l'Académie des Sciences de St-Pétersbourg, VIIe Série Tome XXXI* 7:1-29.

Klein N, and Sander PM. 2008. Ontogenetic stages in the long bone histology of sauropod dinosaurs. *Paleobiology* 34:247-263.

Klevezal GA. 1996. *Recording structures of mammals. Determination of age and reconstruction of life history*. Rotterdam/Brookfield: A.A.Balkema.

Klevezal GA, and Kleinenberg SE. 1969. *Age determination of mammals from annual layers in teeth and bones*. Jerusalem: Israel Program of Scientific Translations.

Köhler M, Marín-Moratalla N, Jordana X, and Aanes R. 2012. Seasonal bone growth and physiology in endotherms shed light on dinosaur physiology. *Nature* 487:358-361.

Köhler M, and Moyà-Solà S. 2009. Physiological and life history strategies of a fossil large mammal in a resource-limited environment. *Proceedings of the National Academy of Sciences of the United States of America* 106:20354-20358.

Kolb C, Scheyer TM, Lister AM, Azorit C, de Vos J, Schlingemann MAJ, Rössner GE, Monaghan NT, and Sánchez-Villagra MR. 2015. Growth in fossil and extant deer and implications for body size and life history evolution. *BMC Evolutionary Biology* 15:1-15.

Kriloff A, Germain D, Canoville A, Vincent P, Sache M, and Laurin M. 2008. Evolution of bone microanatomy of the tetrapod tibia and its use in palaeobiological inference. *Journal of Evolutionary Biology* 21:807-826.

Krmpotic CM, Ciancio MR, Barbeito CG, Mario RC, and Carlini AA. 2009. Osteoderm morphology in recent and fossil euphractine xenarthrans. *Acta Zoologica* 90:339-351.

Laurin M. 2004. The evolution of body size. Cope's rule and the origin of amniotes. *Systematic Biology* 53:594-622.

Laurin M, and Buffrénil V de. 2015. Microstructural features of the femur in early ophiacodontids: a reappraisal of ancestral habitat use and lifestyle of amniotes *Comptes Rendus Palevol*.

Laurin M, Girondot M, and Loth M-M. 2004. The evolution of long bone microanatomy and lifestyle in lissamphibians. *Palaeobiology* 30:589-613.

Lee AH, Huttenlocker AK, Padian K, and Woodward HN. 2013. Analysis of growth rates. In: Padian K, and Lamm E-T, eds. *Bone histology of fossil tetrapods*. Berkeley: University of California Press, 217-251.

Lee AH, and Werning S. 2008. Sexual maturity in growing dinosaurs does not fit reptilian growth models. *Proceedings of the National Academy of Sciences of the United States of America* 105:582-587.

Lomolino MV, Sax DF, Palombo MR, and van der Geer AA. 2012. Of mice and mammoths: evaluations of causal explanations for body size evolution in insular mammals. *Journal of Biogeography* 39:842-854.

Lomolino MV, van der Geer AA, Lyras GA, Palombo MR, Sax DF, and Rozzi R. 2013. Of mice and mammoths: generality and antiquity of the island rule. *Journal of Biogeography* 40:1427-1439.

Luo XZ. 2011. Developmental Patterns in Mesozoic Evolution of Mammal Ears. *Annual Review of Ecology, Evolution, and Systematics* 42:355-380

Luo ZX, and Wible JR. 2005. A Late Jurassic digging mammal and early mammalian diversification. *Science* 308:103-107.

Maddison WP, and Maddison DR. 2015. Mesquite: a modular system for evolutionary analysis. Version 3.02. *Available at http://mesquiteproject.org.*

Mahboubi S, Bocherens H, Scheffler M, Benammi M, and Jaeger JJ. 2014. Was the Early Eocene proboscidean *Numidotherium koholense* semi-aquatic or terrestrial? Evidence from stable isotopes and bone histology. *Comptes Rendus Palevol* 13:501–509.

Marangoni F, Schaefer E, Cajade R, and Tejedo M. 2009. Growth mark formation and chronology of two neotropical anuran species. *Journal of Herpetology* 43:546-550.

Margerie E de, Cubo J, and Castanet J. 2002. Bone typology and growth rate: Testing and quantifying 'Amprino's rule' in the mallard (*Anas platyrhynchus*). *Comptes Rendus Biologies* 325:221-230.

Margerie E de, Robin JP, Verrier D, Cubo J, Groscolas R, and Castanet J. 2004. Assessing a relationship between bone microstructure and growth rate: a fluorescent labelling study in the king penguin chick (*Aptenodytes patagonicus*). *Journal of Experimental Biology* 207:869-879.

Marin-Moratalla N, Cubo J, Jordana X, Moncunill-Solè B, and Köhler M. 2014. Correlation of quantitative bone histology data with life history and climate: a phylogenetic approach. *Biological Journal of the Linnean Society* 112:678-687.

Marin-Moratalla N, Jordana X, and Köhler M. 2013. Bone histology as an approach to providing data on certain key life history traits in mammals: Implications for conservation biology. *Mammalian Biology* 78:422-429.

Martínez-Maza C, Rosas A, and García-Vargas S. 2006. Bone paleohistology and human evolution. *Journal of Anthropological Sciences* 84:33-52.

Martinez-Maza C, Rosas A, Garcia-Vargas S, Estalrrich A, and de la Rasilla M. 2011. Bone remodelling in Neanderthal mandibles from the El Sidron site (Asturias, Spain). *Biology Letters* 7:593e596.

Martiniaková M, Grosskopf B, Vondráková M, Omelka R, and Fabiš M. 2005. Observation of the microstructure of rat cortical bone tissue. *Scripta Medica* 78:45-50.

McNab B. 1994. Resource use and the survival of land and freshwater vertebrates on oceanic islands. *The American Naturalist* 144:643-660.

McNab BK. 2002. Minimizing energy expenditure facilitates vertebrate persistence on oceanic islands. *Ecological Letters* 5:693-704.

McNab BK. 2010. Geographic and temporal correlations of mammalian size reconsidered: a resource rule. *Oecologia* 164:13-23.

Meier PS, Bickelmann C, Scheyer, Koyabu D, and Sánchez-Villagra MR. 2013. Evolution of bone compactness in extant and extinct moles (Talpidae): exploring humeral microstructure in small fossorial mammals. *BMC Evolutionary Biology* 13:55.

Meredith RW, Janecka J, Gatesy J, Ryder OA, Fisher CA, Teeling EC, Goodbla A, Eizirik E, Simão TLL, Stadler T, Rabosky DL, Honeycutt RL, Flynn JJ, Ingram CM, Steiner C, Williams TL, Robinson TJ, Burk-Herrick A, Westerman M, Ayoub NA, Springer MS, and Murphy WJ. 2011. Impacts of the Cretaceous terrestrial revolution and KPg extinction on mammal diversification. *Science* 334:521-524.

Mitchell EDJ. 1963. Brachydont desmostylian from Miocene of San Clemente Island, California. *Bulletin of the Southern California Academy of Science* 62:192-201.

Mitchell EDJ. 1964. Pachyostosis in desmostylids. *The Geological Society of America Special Paper* 76:214.

Mitchell J, and Sander PM. 2014. The three-front model: a developmental explanation of long bone diaphyseal histology of Sauropoda. *Biological Journal of the Linnean Society* 112:765–781.

Morris P. 1970. A method for determining absolute age in the hedgehog. *Journal of Zoology* 161:277-281.

Musser AM, and Archer M. 1998. New information about the skull and dentary of the Miocene *Platypus obdurodon dicksoni*, and a discussion of ornithorhynchid relationships. *Philosophical Transactions of the Royal Society of London B* 353:1063-1079.

Nasterlack T, Canoville A, and Chinsamy A. 2012. New insights into the biology of the Permian genus *Cistecephalus* (Therapsida, Dicynodontia). *Journal of Vertebrate Paleontology* 32:1396-1410.

Nopcsa F von, and Heidsieck E. 1933. On the histology of the ribs of immature and half-grown trachodont dinosaurs. *Proceedings of the Zoological Society of London* 1:221-223.

Nopcsa F von, and Heidsieck E. 1934. Über eine pachyostotische Rippe aus der Kreide Rügens. *Acta Zoologica* 15:431-455.

O'Leary MA, Bloch JI, Flynn JJ, Gaudin TJ, Giallombardo A, Giannini NP, Goldberg SL, Kraatz BP, Luo Z-X, Meng J, Ni X, Novacek MJ, Perini FA, Randall ZS, Rougier GW, Sargis EJ, Silcox MT, Simmons NB, Spaulding M, Velazco PM, Weksler M, Wible JR, and Cirranello AL. 2013. The Placental Mammal Ancestor and the Post-K-Pg Radiation of Placentals. *Science* 339:662-667.

O'Leary MA, and Kaufman SG. 2012. MorphoBank 3.0: web application for morphological phylogenetics and taxonomy. *Available at http://www.morphobank.org* (accessed 6 May 2015).

Padian K. 2011. Vertebrate palaeohistology then and now: A retrospective in the light of the contributions of Armand de Ricqles. *Comptes Rendus Palevol* 10:303-309.

Padian K. 2013. Book review: forerunners of mammals: radiation, histology, biology. *Journal of Vertebrate Paleontology* 33:1250-1251.

Padian K, and Lamm E-T. 2013. Bone histology of tetrapods. Berkeley, Los Angeles: University of California Press. p 285.

Pascal M, and Castanet J. 1978. Méthodes de la détermination de l'age chez le chat haret des iles Kerguelen. *Terre et Vie* 32:529-554.

Pascal M, and Delattre P. 1981. Comparaison des différentes méthodes de la détermination de l'age individuel chez le vison (*Mustela vison* Schreber). *Canadian Journal of Zoology* 59:202-211.

Pascual R, Archer M, Jaureguizar EO, Prado JL, Godthelp H, and Hand SJ. 1992. First discovery of monotremes in South America. *Nature* 356:704 - 706.

Pazzaglia UE, Sibilia V, Congiu T, Pagani F, Ravanelli M, and Zarattini G. 2015. Setup of a bone aging experimental model in the rabbit comparing changes in cortical and trabecular bone: morphological and morphometric study in the femur. *Journal of Morphology*.

Peabody FE. 1961. Annual growth zones in living and fossil vertebrates. *Journal of Morphology* 108:11-62.

Ponton F, Elzanowski A, Castanet J, Chinsamy A, Margerie E de, Ricqlès A de, and Cubo J. 2004. Variation of the outer circumferential layer in the limb bones of birds. *Acta Ornithologica* 39:21-24.

Prondvai E, Stein KHW, Ricqlès A de, and Cubo J. 2014. Development-based revision of bone tissue classification: the importance of semantics for science. *Biological Journal of the Linnean Society* 112:799-816.

Quekett JT. 1849a. On the intimate structure of bone as composing the skeleton in the four great classes of animals, viz., mammals, birds, reptiles, and fishes, with some remarks on the great value of the knowledge of such structure in determining the affinities of minute fragments of organic remains. *Transactions of the Microscopical Society of London* 2:46-58.

Quekett JT. 1849b. Additional observations on the intimate structure of bone. *Transactions of the Microscopical Society of London* 2:59-64.

Quekett JT. 1855. *Descriptive and illustrated catalogue of the histological series contained in the museum of the Royal College of Surgeons of England. Volume II. Structure of the skeleton of vertebrate animals*. London: Taylor and Francis.

Raia P, Barbera C, and Conte M. 2003. The fast life of a dwarfed giant. *Evolutionary Ecology* 17:293-312.

Ray S, Bandyopadhyay S, and Appana R. 2010. Bone histology of a kannemeyeriid dicynodont *Wadiasaurus*: palaeobiological implications. In: Bandyopadhyay S, ed. *New aspects of mesozoic biodiversity*. Heidelberg: Springer, 73-89.

Ray S, Botha J, and Chinsamy A. 2004. Bone histology and growth patterns of some nonmammalian therapsids. *Journal of Vertebrate Paleontology* 24:634-648.

Ray S, Botha-Brink J, and Chinsamy-Turan A. 2012. Microstructure of bones and teeth of nonmammalian therapsids. In: Chinsamy-Turan A, ed. *Forerunners of mammals: radiation, histology, biology*. Bloomington: Indiana University Press, 121-146.

Ray S, and Chinsamy A. 2004. *Diictodon feliceps* (Therapsida, Dicynodontia): bone histology, growth, and biomechanics. *Journal of Vertebrate Paleontology* 24:180-194.

Ray S, Chinsamy A, and Bandyopadhyay S. 2005. *Lystrosaurus murrayi* (Therapsida, Dicynodontia): bone histology, growth and lifestyle adaptations. *Palaeontology* 48:1169-1185.

Rega E, Sumida SS, Noriega K, Pell C, and Lee A. 2005. Evidence-based paleopathology I: ontogenetic and functional implications of dorsal sails in *Dimetrodon*. *Journal of Vertebrate Paleontology* 25:103A.

Ricqlès A de. 1969. Recherches palèohistologiques sur les os longs des tetrapodes. II.- Quelques observations sur la structure des os longs des thériodontes. *Annales de Paléontologie* 55:1-52.

Ricqlès A de. 1972. Recherches palèohistologiques sur les os longs des tetrapodes. III.- Titanosuchiens, dinocéphaliens et dicynodontes. *Annales de Paléontologie (Vertébrés)* 58:17-46.

Ricqlès A de. 1974a. Evolution of endothermy: histological evidence. *Evolutionary Theory* 1:51-80.

Ricqlès A de. 1974b. Recherches paléohistologiques sur les os longs des tétrapodes. IV. - Éothériodontes et pélycosaures. *Annales de Paléontologie* 60:1-56.

Ricqlès A de. 1975. Recherches paléohistologiques sur les os longs des tétrapodes VII. - Sur la classification, la signification fonctionnelle et l'histoire des tissus oseux des tétrapodes. Première partie, structures. *Annales de paléontologie 61, 51-129* 61:51-129.

Ricqlès A de. 1976a. On bone histology of fossil and living reptiles, with comments on its functional and evolutionary significance. In: Bellairs A, and Cox CB, eds. *Morphology and Biology of Reptiles*. London and New York: Academic Press, 123-150.

Ricqlès A de. 1976b. Recherches paléohistologiques sur les os longs des tétrapodes. VII. - Sur la classification, la signification fonctionnelle et l'histoire des tissus osseux des tétrapodes. Deuxième partie. Fonctions: considérations fonctionnelles et physiologiques. *Annales de Paléontologie* 62:71-126.

Ricqlès A de. 1978. Recherches paléohistologiques sur les os longs des tétrapodes. VII. — Sur la classification, la signification fonctionnelle et l'histoire des tissus osseux des tétrapodes. Troisième partie. IV.-Les problèmes du déterminisme des types de tissus osseux. *Annales de Paléontologie* 64:153-184.

Ricqlès A de, and Buffrénil V de. 1995. Sur la présence de pachyostéosclerosis chez la rhytine de Steller (*Rhytina* (*Hydrodamalis*) *gigas*), sirénian rézent éteint. *Annales des Sciences Naturelles, Zoologie, Paris, 13e Série* 16:47-53.

Ricqlès A de, Castanet J, and Francillon-Vieillot H. 2004. The "message" of bone tissue in Palaeoherpetology. *Italian Journal of Zoology*:3-12.

Ricqlès A de, and Cubo J. 2010. Le problème de la causalité complexe aux sources de la relation structuro-fonctionnelle : 1/généralités, 2/l'exemple du tissu osseux. In: Gayon J, and Ricqlès Ad, eds. *Les Fonctions : des organismes aux artefacts*. Paris: PUF, 179-188.

Ricqlès A de, Meunier FJ, Castanet J, and Francillon-Vieillot H. 1991. Comparative microstructure of bone. In: Hall BK, ed. *Bone Volume 3: Bone matrix and bone specific products*. Boca Raton: CRC Press, 1-78.

Ricqlès A de, Taquet P, and Buffrenil V de. 2009. "Rediscovery" of Paul Gervais' paleohistological collection. *Geodiversitas* 31:943-971.

Ricqlès A de. 2011. Vertebrate palaeohistology: past and future. *Comptes Rendus Palevol* 10:509–515.

Romer AS. 1957. Origin of the amniote egg. *Scientific monthly* 85:57-63.

Romer AS. 1958. Tetrapod limbs and early tetrapod life. *Evolution* 12:365-369.

Rubidge BS, and Sidor CA. 2001. Evolutionary patterns among Permo-Triassic therapsids. *Annual Review of Ecology and Systematics* 32:449-480.

Ryan TM, and Shaw CN. 2015. Gracility of the modern *Homo sapiens* skeleton is the result of decreased biomechanical loading. *Proceedings of the National Academy of Sciences of the United States of America* 112:372-377.

Sanchez S, Ahlberg P, Trinajstic K, Mirone A, and Tafforeau P. 2012. Three dimensional synchrotron virtual paleohistology: a new insight into the world of fossil bone microstructures. *Microscopy and Microanalysis* 18:1095-1105.

Sander PM. 2000. Longbone histology of the Tendaguru sauropods: implications for growth and biology. *Paleobiology* 26:466-488.

Sander PM, and Andrassy P. 2006. Lines of arrested growth and long bone histology in Pleistocene large mammals from Germany: What do they tell us about dinosaur physiology? *Palaeontographica Abteilung A* 277:143-159.

Sander PM, Klein N, Buffetaut E, Cuny G, Suteethorn V, and Le Loeuff J. 2004. Adaptive radiation in sauropod dinosaurs: bone histology indicates rapid evolution of giant body size through acceleration. *Organisms, Diversity & Evolution* 4:165-173.

Sander PM, and Tückmantel C. 2003. Bone lamina thickness, bone apposition rates, and age estimates in sauropod humeri and femora. *Paläontologische Zeitschrift* 77:161-172.

Schaffer J. 1890. Über den feineren Bau fossiler Knochen. *Sitzungsberichte der Kaiserlichen Akademie der Wissenschaften* Mathematisch-Naturwissenschaftliche Classe XCVIII. Band. Hefte I bis X. Abtheilung III:319-382.

Scheyer TM. 2009-2015. Palaeohistology. In: Sánchez-Villagra MR, editor. Developmental - Palaeontology net. Zurich: Palaeontological Institute of the University of Zurich. *Available at http://www.developmental-palaeontology.net/palaeohistology/index.php* (accessed 1 June 2015).

Scheyer TM, Klein N, and Sander PM. 2010. Developmental palaeontology of Reptilia as revealed by histological studies. *Seminars in Cell & Developmental Biology* 21:462-470.

Schultz M. 1997. Microscopic investigation of excavated skeletal remains: a contribution to paleopathology and forensic medicine. In: Haglund WD, and Sorg MH, eds. *Forensic taphonomy The postmortem fate of human remains*. Boca Raton/New York/London/Tokyo: CRC Press, 201-222.

Schultz M, and Schmidt-Schultz TH. 2014. Microscopic research on fossil human bone. In: Henke W, and Tattersall I, eds. *Handbook of paleoanthropology*. 2nd ed. Heidelberg/New York: Springer, 983-998.

Shelton C, and Sander PM. 2015. *Ophiacodon* long bone histology: the earliest occurrence of FLB in the mammalian stem lineage. *PeerJ PrePrints* Available at https://dx.doi.org/10.7287/peerj.preprints.1027v1 (accessed 11 May 2015).

Shelton CD, Sander PM, Stein K, and Winkelhorst H. 2013. Long bone histology indicates sympatric species of Dimetrodon (Lower Permian, Sphenacodontidae). *Earth and Environmental Science Transactions of the Royal Society of Edinburgh* 103:1-20.

Sigurdsen T, Huttenlocker AK, Modesto SP, Rowe T, and Damiani R. 2012. Reassessment of the morphology and paleobiology of the therocephalian *Tetracynodon darti* (Therapsida), and the phylogenetic relationships of Baurioidea. *Journal of Vertebrate Paleontology* 32:1113-1134.

Singh IJ, Tonna EA, and Gandel CP. 1974. A comparative histological study of mammalian bone. *Journal of Morphology* 144:421-438.

Skinner MM, Stephens NB, Tsegai ZJ, Foote AC, Nguyen NH, Gross T, Pahr DH, Hublin J-J, and Kivell TL. 2015. Human-like hand use in *Australopithecus africanus*. *Science* 347:395–399.

Stein K, and Prondvai E. 2013. Rethinking the nature of fibrolamellar bone: an integrative biological revision of sauropod plexiform bone formation. *Biological Reviews*:1-24.

Stein K, and Sander M. 2009. Histological core drilling: a less destructive method for studying bone histology. First Annual Fossil Preparation and Collections Symposium. Petrified Forest National Park: Petrified Forest. p 69-80.

Straehl FR, Scheyer TM, Forasiepi AM, MacPhee RD, and Sánchez-Villagra MR. 2013. Evolutionary patterns of bone histology and bone compactness in xenarthran mammal long bones. *Plosone* 8:e69275.

Tacutu R, Craig T, Budovsky A, Wuttke D, Lehmann G, Taranukha D, Costa J, Fraifeld VE, and de Magalhaes JP. 2013. Human Ageing Genomic Resources: Integrated databases and tools for the biology and genetics of ageing. *Nucleic Acids Research* 41:D1027-D1033.

Thewissen JGM, Cooper LN, Clementz MT, Bajpai S, and Tiwari BN. 2007. Whales originated from aquatic artiodactyls in the Eocene epoch of India. *Nature* 450:1190-1194.

Tomassini RL, Montalvo CI, Manera T, and Visconti G. 2014. Mineralogy, geochemistry, and paleohistology of pliocene mammals from the Monte Hermoso Formation (Argentina). *Paedotherium bonaerense* (Notoungulata, Hegetotheriidae) as a case study. *Ameghiniana* 51:385-395.

van der Geer A, Lyras G, de Vos J, and Dermitzakis M. 2010. *Evolution of island mammals. Adaptation and extinction of placental mammals on islands*. Sussex: Wiley-Blackwell.

Vanderhoof VL. 1937. A study of the Miocene sirenian *Desmostylus*. *University of California Publications in the Geological Sciences* 24:169-262.

Vickaryous MK, and Hall BK. 2006. Osteoderm morphology and development in the nine-banded armadillo, *Dasypus novemcinctus* (Mammalia, Xenarthra, Cingulata). *Journal of Morphology* 267:1273-1283.

Vickaryous MK, and Sire JY. 2009. The integumentary skeleton of tetrapods: origin, evolution, and development. *Journal of Anatomy* 214:441-464.

Warren JW. 1963. Growth zones in the skeleton of recent and fossil vertebrates PhD. University of California.

Wolf D. 2007. Osteoderm histology of extinct and recent Cingulata and Phyllophaga (Xenarthra, Mammalia): implications for systematics and biomechanical adaptation. *Hallesches Jahrbuch für Geowissenschaften* Beiheft 23:145-151.

Wolf D. 2008. Osteoderm histology of the Cingulata (Xenarthra, Mammalia): implications for systematics. *Journal of Vertebrate Paleontology* 28:161A.

Wolf D, Kalthoff DC, and Martin Sander PM. 2012. Osteoderm histology of the Pampatheriidae (Cingulata, Xenarthra, Mammalia): implications for systematics, osteoderm growth, and biomechanical adaptation. *Journal of Morphology* 273:388-404.

Woodward HN, Padian K, and Lee AH. 2013. Skeletochronology. In: Padian K, and Lamm E-T, eds. *Histology of fossil tetrapods - Advancing methods, analysis and interpretation*. Berkeley, Los Angeles, London: University of California Press, 195-215.

Zedda M, Lepore G, Manca P, Chisu V, and Farina V. 2008. Comparative bone histology of adult horses and cows. *Journal of Veterinary Medicine Series C* 37:442–445.

Zylberberg L, Traub W, Buffrénil V de, Allizard F, Arad T, and Weiner S. 1998. Rostrum of a toothed whale: ultrastructural study of a very dense bone. *Bone* 23:241-247.

1492 **Figure captions**

1493 **Figure 1: Typical mammalian bone tissue as observed in large mammals such as cervids.**
1494 Red bars indicate area and plane of sectioning. Histological images B), E), and I) in linear
1495 polarised light, C) in crossed polarised light and with additional use of lambda
1496 compensator, and F) in crossed polarised light. A) Life reconstruction of the cervid
1497 *Megaloceros giganteus* ("Knight Megaloceros" by Charles R. Knight, courtesy of the
1498 American Museum of Natural History via Wikimedia Commons -
1499 http://commons.wikimedia.org). B, C) Bone cortex of a tibia of *Megaloceros giganteus*
1500 specimen NMING:F21306/14 displaying an endosteal lamellar layer (innermost part of
1501 the cortex) and reticular as well as plexiform fibrolamellar primary bone with growth
1502 marks. Note that the primary bone is pervaded by secondary Haversian systems in the
1503 inner third of the bone cortex. White arrows indicate lines of arrested growth. Occurrence
1504 of LAGs indicated by black/white arrows and the outer circumferential layer (OCL) by
1505 white brackets. D) Photograph of *Pudu puda* ("Pudupuda hem 8 FdoVidal Villarr
1506 08Abr06-PhotoJimenez", courtesy of Jaime E. Jimenez via Wikimedia Commons -
1507 http://commons.wikimedia.org). E, F) Bone cortex of a femur of *Pudu puda* specimen
1508 NMW 60135 displaying an endosteal lamellar layer and mainly plexiform fibrolamellar
1509 bone. G) Reconstruction of *Paraceratherium* ("Indricotherium11", Courtesy of Dmitry
1510 Bogdanov via Wikimedia Commons - http://commons.wikimedia.org). H) Cross-section
1511 of a rib of *Paraceratherium* sp. specimen MTA-TTM 2006-1209. Red rectangle indicates
1512 area of dense Haversian bone magnified in I).

1513 **Figure 2: Phylogeny of basal synapsids focussing on groups discussed,** based on Rubidge &
1514 Sidor (2001), Benson (2012), and Brink & Reisz (2014.

Figure 3: Phylogeny of Mammaliamorpha focussing on groups discussed, based on Luo et al. (2005), Luo et al. (2011), Meredith et al. (2011), and O'Leary et al. (2013). Notoungulates and Pantodonta are not included given their controversial systematic position.

Figure 4: Femoral bone cortex of marsupials. Histological images A) and D) in linear polarised light and B), C), E), and F) in crossed polarised light. A, B) Outer bone cortex of adult *Didelphis albiventris* specimen PIMUZ A/V 5279. Note the occurrence of simple primary longitudinal vascular canals and primary osteons in mainly parallel-fibred bone tissue. C) Inner bone cortex of the same specimen displaying a distinct endosteal lamellar layer. D, E) Bone cortex of adult *Lutreolina crassicautada* specimen PIMUZ A/V 5275. F) Inner cortex of same specimen. Note the occurrence of primary longitudinal vascular canals and primary osteons as well as Haversian systems within the parallel-fibred bone.

Figure 5: Histological features of the femur of *Deinogalerix* sp. A) Life reconstruction of *Deinogalerix koenigswaldi* in comparison to the extant hedgehog *Erinaceus* (modified from Agustí & Antón, 2002). B) Adult right femur (specimen RGM.178017) in anterior view. Red bar indicates area and plane of sectioning. C) Lateral bone cortex in crossed polarised light showing parallel-fibred bone and 5 LAGs. Occurrence of LAGs indicated by white arrows.

Figure 6: Bone cortex of *Hippopotamus minor* femora. A) Life reconstruction (from van der Geer et al., 2010; drawing: Alexis Vlachos) of another Mediterranean dwarf hippopotamid from the Middle Pleistocene of Crete. Since no life reconstruction of *Hippopotamus minor* is available, we here show the one of *Hippopotamus creutzburgi*. Histological images B), and C) in linear polarised light, D) in crossed polarised light. B)

Small juvenile specimen CKS 110/B. C) Intermediate sized juvenile specimen CKS 122/B showing reticular to plexiform vascularised bone. Note that the central part mainly consists of reticular bone. D) Outer bone cortex of large juvenile specimen CKS 117 showing mainly parallel-fibred bone. Black and grey areas indicate zones of recrystallisation due to diagenetic alteration of bone tissue.

Figure 7: Histological features of *Sinomegaceros yabei*, the megacerine deer from the Pleistocene of Japan. Histological images in linear polarised light of an adult femur (OMNH QV-4062) depicting A) the whole cross-section and B) a close-up of the outer cortex. The red bar in A) localizes the approximated position of the section on the life reconstruction (courtesy of Hirokazu Tokugawa), and the red rectangle indicates the area of the close-up. B) Note that seven LAGs are visible, as indicated by white arrows.

Figure 8: Bone histology of fossil island rodents. Histological images A) and D) in linear polarised light, B) and E) in crossed polarised light, and C) and F) in crossed polarised light with additional use of lambda compensator. A-C) Adult *Mikrotia* sp. femur (specimen RGM.792085) showing disorganised, parallel-fibred/lamellar bone in its centre. D-F) Adult femur of *Leithia* sp. specimen NMB G 2160 displaying lamellar bone being pervaded by longitudinal to radial primary osteons and irregularly shaped and partially oblique secondary osteons.

Figure 9: Bone histology of fossil ochotonids. A) Life reconstruction of *Prolagus sardus* ("Prolagus3", courtesy of Wikimedia Commons - http://commons.wikimedia.org). Histological images B), D), F) in linear polarised light and C) and E) in crossed polarised light with additional use of lambda compensator. B, C) Lateral cortex of *Prolagus oeningensis* femur PIMUZ A/V 4532 showing subendosteal Haversian-like bone in the

inner part and parallel-fibred bone in the central and outer part as well as three LAGs. D, E) Lateral cortex of *Prolagus imperialis* femur RGM.792094 displaying an identical pattern of bone tissue but five LAGs. F) Outer anterolateral cortex of *Prolagus sardus* femur NMB Ty.12659 displaying five LAGs. Note that the line in the lower third of the cortex is a resorption line (RL) and not a LAG. Occurrence of LAGs indicated by white or yellow arrows.

Table 1(on next page)

Table 1: Material used in this study.

Specimens sampled in this study with ontogenetic stage, geological age, locality of death/fossil site, and specimen number.

Institutional Abbreviations: **CKS** Cyprus Kissonerga collection of the University of Athens; **MTA** Natural History Museum, The General Directorate of Mineral Research and Exploration, Ankara, Turkey; **NMB** Naturhistorisches Museum Basel, Switzerland; **NMING** National Museum of Ireland - Natural History; **NMW** Naturhistorisches Museum Wien, Austria; **OMNH** Osaka Museum of Natural History, Japan; **PIMUZ** Paläontologisches Institut und Museum, Universität Zürich, Switzerland; **RGM** Rijksmuseum voor Geologie en Mineralogie (now Netherlands Centre for Biodiversity Leiden)

2 **Table 1: Material used in this study.** Specimens sampled in this study with ontogenetic stage,

3 geological age, locality of death/fossil site, and specimen number.

Species	Object	Ontogenetic stage	Geological age; Locality	Specimen number
Megaloceros giganteus	Tibia	adult	Late Pleistocene; Baunmore Townland, Rep. of Ireland	NMING:F21306/14
Sinomegaceros yabei	Tibia	juvenile	Late Pleistocene; Kumaishi-do Cave, Miyama, Hachiman-cho, Gujo City, Gifu Prefecture, Japan	OMNH QV-4067
"	Tibia	adult	"	OMNH QV-4068
"	Femur	juvenile	"	OMNH M-087
"	Femur	adult	"	OMNH QV-4062
Pudu puda	Femur		Tiergarten Schönbrunn, Vienna, Austria	NMW 60135
Didelphis albiventris	Femur	adult	La Plata, Argentina	PIMUZ A/V 5279
"	"	adult	"	PIMUZ A/V 5277
"	"	adult	Ingeniero Mashwitzt, Argentina	PIMUZ A/V 5276
"	"	adult	Ranchos, Argentina	PIMUZ A/V 5278
Lutreolina crassicautada	"	adult	Mar de Ajo, Argentina	PIMUZ A/V 5275
"	"	adult	La Plata, Argentina	PIMUZ A/V 5274
Hippopotamus minor	"	juvenile	Late Pleistocene; Kissonerga, Cyprus	CKS 110/B
"	"	juvenile	"	CKS 122/B
"	"	subadult	"	CKS 117
"	Tibia	adult	"	CKS 215

Leithia sp.	"	adult	Pleistocene; Grotta di Maras, Sicily	NMB G 2160
Deinogalerix sp.	Femur	adult	Late Miocene; Gervasio 1, Gargano, Italy	RGM.178017
"	Humerus	adult	Late Miocene; Chiro 20E, Foggia, Gargano, Italy	RGM.425360
Mikrotia magna	Femur	adult	Late Miocene; Sono Giovo, Gargano	RGM.792083
"	"	adult	"	RGM.792084
"	"	adult	"	RGM.792085
"	"	adult	"	RGM.792086
Prolagus apricenicus	Femur	adult	Late Miocene; San Giovannino, Gargano	RGM.792087
"	"	adult	"	RGM.792088
"	"	adult	"	RGM.792089
"	"	adult	"	RGM.792090
"	"	adult	"	RGM.792091
"	"	adult	"	RGM.702092
"	Humerus	adult	"	RGM.792093
"	"	adult	"	RGM.792094
"	"	adult	"	RGM.792095
Prolagus imperialis	Femur	adult	"	RGM.792096
"	"	adult	"	RGM.792097
"	"	adult	"	RGM.792098
"	"	adult	"	RGM.792099
"	"	adult	"	RGM.792100
"	"	adult	"	RGM.792101
"	Humerus	juvenile	"	RGM.792102

"	"	adult	"	RGM.792103
"	"	adult	"	RGM.792104
Prolagus sardus	Femur	juvenile	Late Pleistocene; Monte San Giovanni, Sardinia	NMB Ty. 4974
"	"	adult	"	NMB Ty. 4977
"	"	adult	Late Pleistocene; Grotta Nicolai, Sardinia	NMB Ty.12656
"	"	adult	"	NMB Ty.12657
"	"	adult	Late Pleistocene; Isola di Tavolara, Sardinia	NMB Ty.12658
"	"	adult	"	NMB Ty.12659
Prolagus oeningensis	Femur	juvenile	Middle Miocene; La Grive, France	PIMUZ A/V 4532
	"	adult		PIMUZ A/V 4532
"	"	adult	"	PIMUZ A/V 4532
"	Humerus	adult	"	PIMUZ A/V 4532
"	"	adult	"	PIMUZ A/V 4532
Paraceratherium sp.	Rib	adult	Late Oligocene; Gözükizilli, Turkey	MTA-TTM 2006-1209

Institutional Abbreviations: **CKS** Cyprus Kissonerga collection of the University of Athens; **MTA** Natural History Museum, The General Directorate of Mineral Research and Exploration, Ankara, Turkey; **NMB** Naturhistorisches Museum Basel, Switzerland; **NMING** National Museum of Ireland - Natural History; **NMW** Naturhistorisches Museum Wien, Austria; **OMNH** Osaka Museum of Natural History, Japan; **PIMUZ** Paläontologisches Institut und Museum, Universität Zürich, Switzerland; **RGM** Rijksmuseum voor Geologie en Mineralogie (now Netherlands Centre for Biodiversity Leiden)

1

Figure 1: Typical mammalian bone tissue as observed in large mammals such as cervids.

Red bars indicate area and plane of sectioning. Histological images B), E), and I) in linear polarised light, C) in crossed polarised light and with additional use of lambda compensator, and F) in crossed polarised light. A) Life reconstruction of the cervid *Megaloceros giganteus* ("Knight Megaloceros" by Charles R. Knight, courtesy of the American Museum of Natural History via Wikimedia Commons - http://commons.wikimedia.org). B, C) Bone cortex of a tibia of *Megaloceros giganteus* specimen NMING:F21306/14 displaying an endosteal lamellar layer (innermost part of the cortex) and reticular as well as plexiform fibrolamellar primary bone with growth marks. Note that the primary bone is pervaded by secondary Haversian systems in the inner third of the bone cortex. White arrows indicate lines of arrested growth. Occurrence of LAGs indicated by black/white arrows and the outer circumferential layer (OCL) by white brackets. D) Photograph of *Pudu puda* ("Pudupuda hem 8 FdoVidal Villarr 08Abr06-PhotoJimenez", courtesy of Jaime E. Jimenez via Wikimedia Commons - http://commons.wikimedia.org). E, F) Bone cortex of a femur of *Pudu puda* specimen NMW 60135 displaying an endosteal lamellar layer and mainly plexiform fibrolamellar bone. G) Reconstruction of *Paraceratherium* ("Indricotherium11", Courtesy of Dmitry Bogdanov via Wikimedia Commons - http://commons.wikimedia.org). H) Cross-section of a rib of *Paraceratherium* sp. specimen MTA-TTM 2006-1209. Red rectangle indicates area of dense Haversian bone magnified in I).



2

Figure 2: Phylogeny of basal synapsids focussing on groups discussed,

based on Rubidge & Sidor (2001), Benson (2012), and Brink & Reisz (2014).

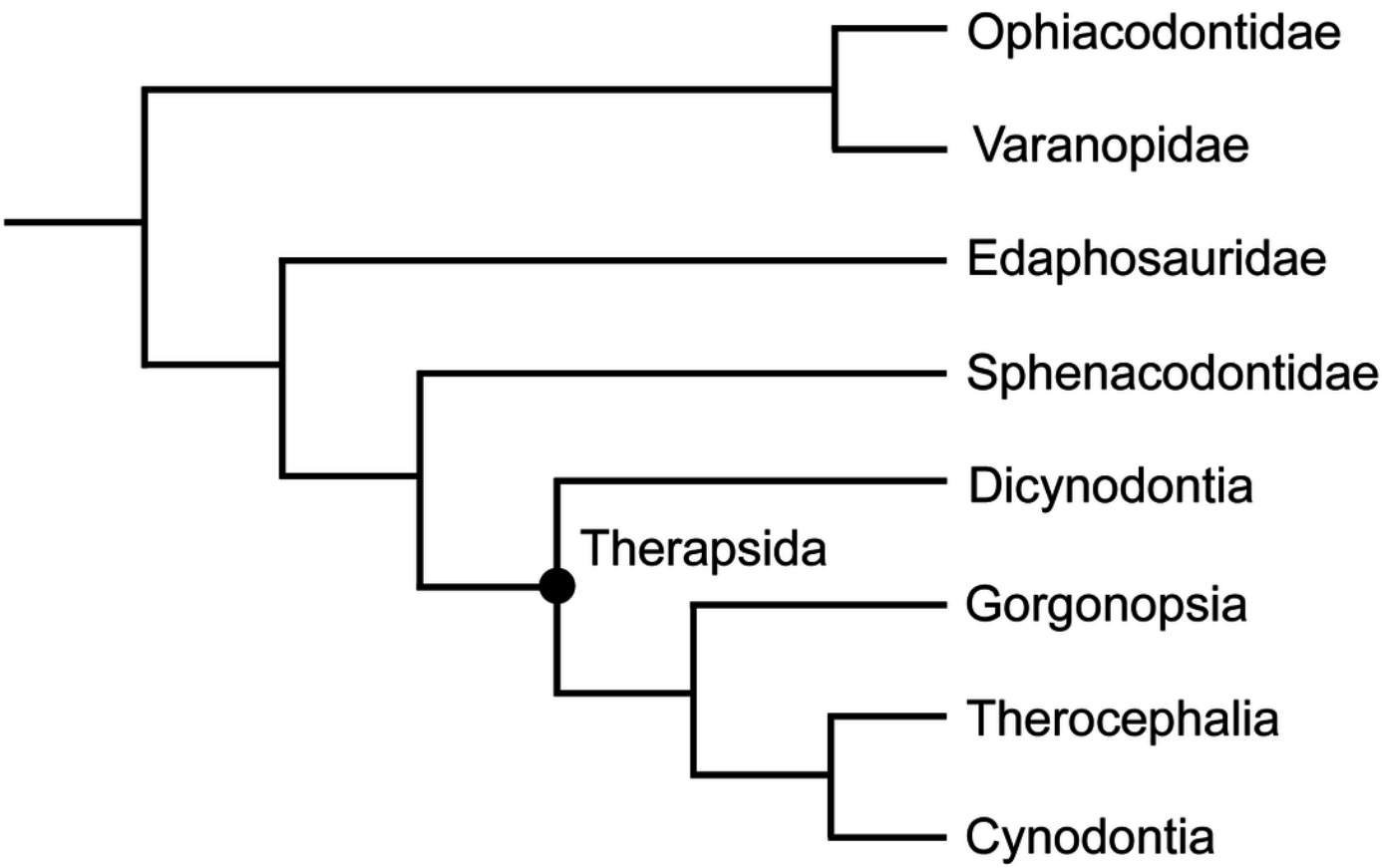

3

Figure 3: Phylogeny of Mammaliamorpha focussing on groups discussed,

based on Luo et al. (2005), Luo et al. (2011), Meredith et al. (2011), and O'Leary et al. (2013). Notoungulates and Pantodonta are not included given their controversial systematic position.

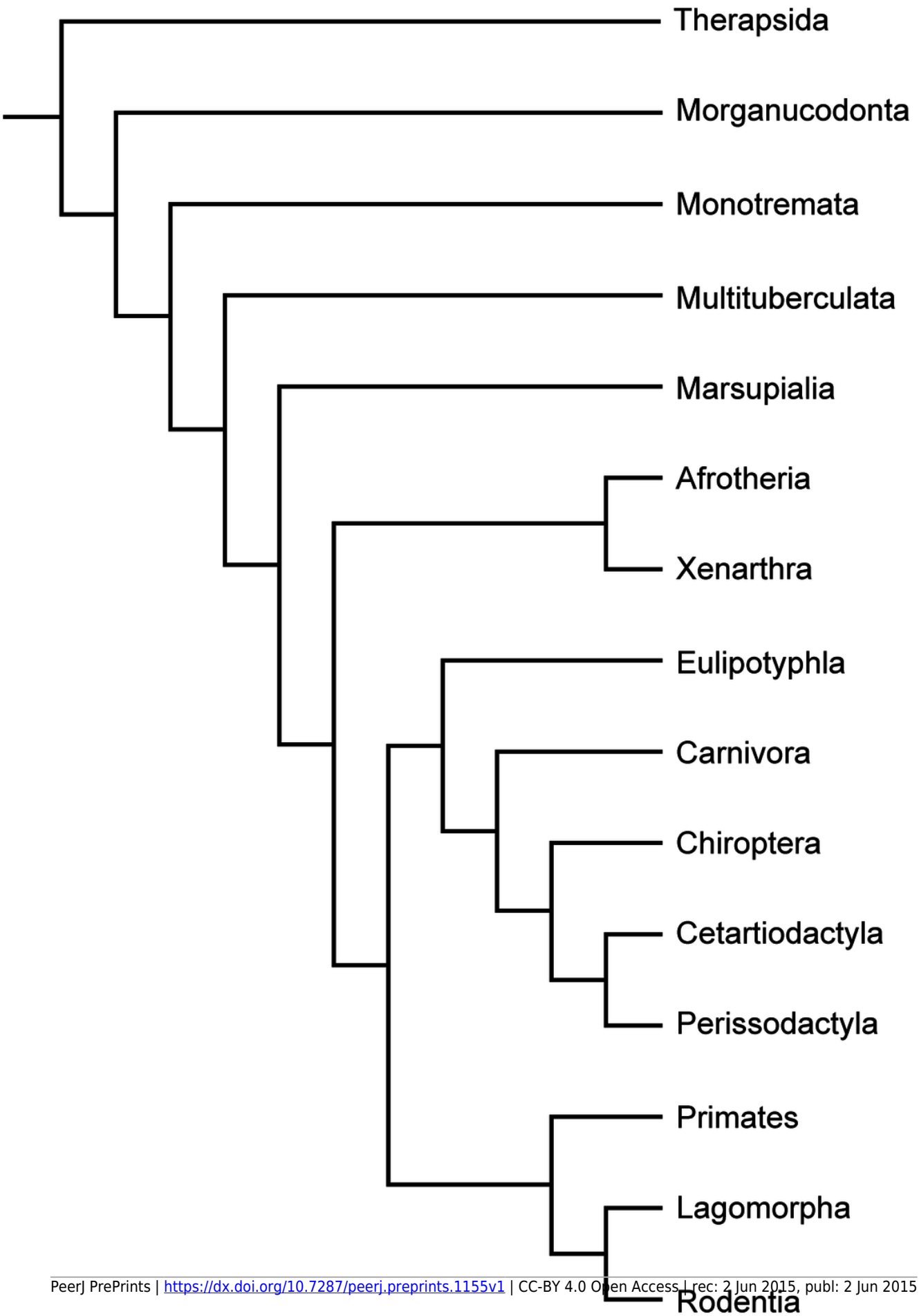

PeerJ PrePrints | https://dx.doi.org/10.7287/peerj.preprints.1155v1 | CC-BY 4.0 Open Access | rec: 2 Jun 2015, publ: 2 Jun 2015

4

Figure 4: Femoral bone cortex of marsupials.

Histological images A) and D) in linear polarised light and B), C), E), and F) in crossed polarised light. A, B) Outer bone cortex of adult *Didelphis albiventris* specimen PIMUZ A/V 5279. Note the occurrence of simple primary longitudinal vascular canals and primary osteons in mainly parallel-fibred bone tissue. C) Inner bone cortex of the same specimen displaying a distinct endosteal lamellar layer. D, E) Bone cortex of adult *Lutreolina crassicautada* specimen PIMUZ A/V 5275. F) Inner cortex of same specimen. Note the occurrence of primary longitudinal vascular canals and primary osteons as well as Haversian systems within the parallel-fibred bone.



5

Figure 5: Histological features of the femur of *Deinogalerix* sp.

A) Life reconstruction of *Deinogalerix koenigswaldi* in comparison to the extant hedgehog *Erinaceus* (modified from Agustí & Antón, 2002). B) Adult right femur (specimen RGM.178017) in anterior view. Red bar indicates area and plane of sectioning. C) Lateral bone cortex in crossed polarised light showing parallel-fibred bone and 5 LAGs. Occurrence of LAGs indicated by white arrows.

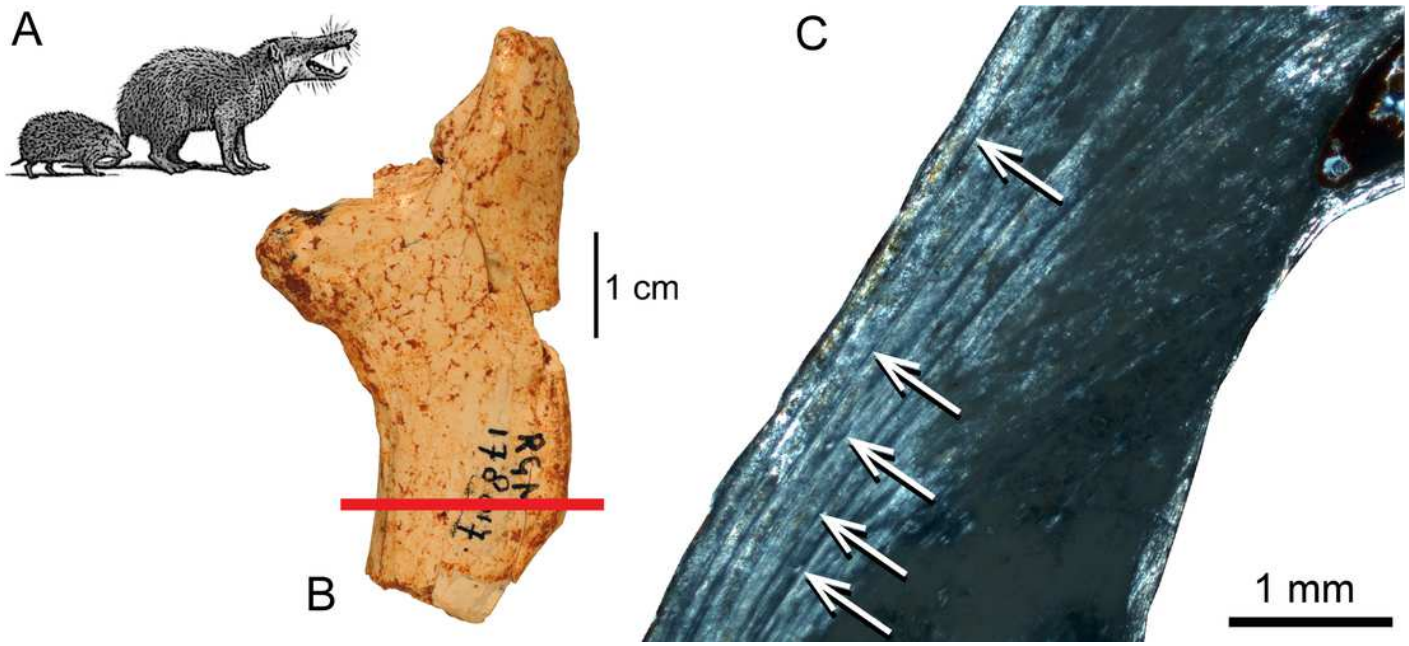

6

Figure 6: Bone cortex of *Hippopotamus minor* femora.

A) Life reconstruction (from van der Geer et al., 2010; drawing: Alexis Vlachos) of another Mediterranean dwarf hippopotamid from the Middle Pleistocene of Crete. Since no life reconstruction of *Hippopotamus minor* is available, we here show the one of *Hippopotamus creutzburgi*. Histological images B), and C) in linear polarised light, D) in crossed polarised light. B) Small juvenile specimen CKS 110/B. C) Intermediate sized juvenile specimen CKS 122/B showing reticular to plexiform vascularised bone. Note that the central part mainly consists of reticular bone. D) Outer bone cortex of large juvenile specimen CKS 117 showing mainly parallel-fibred bone. Black and grey areas indicate zones of recrystallisation due to diagenetic alteration of bone tissue.

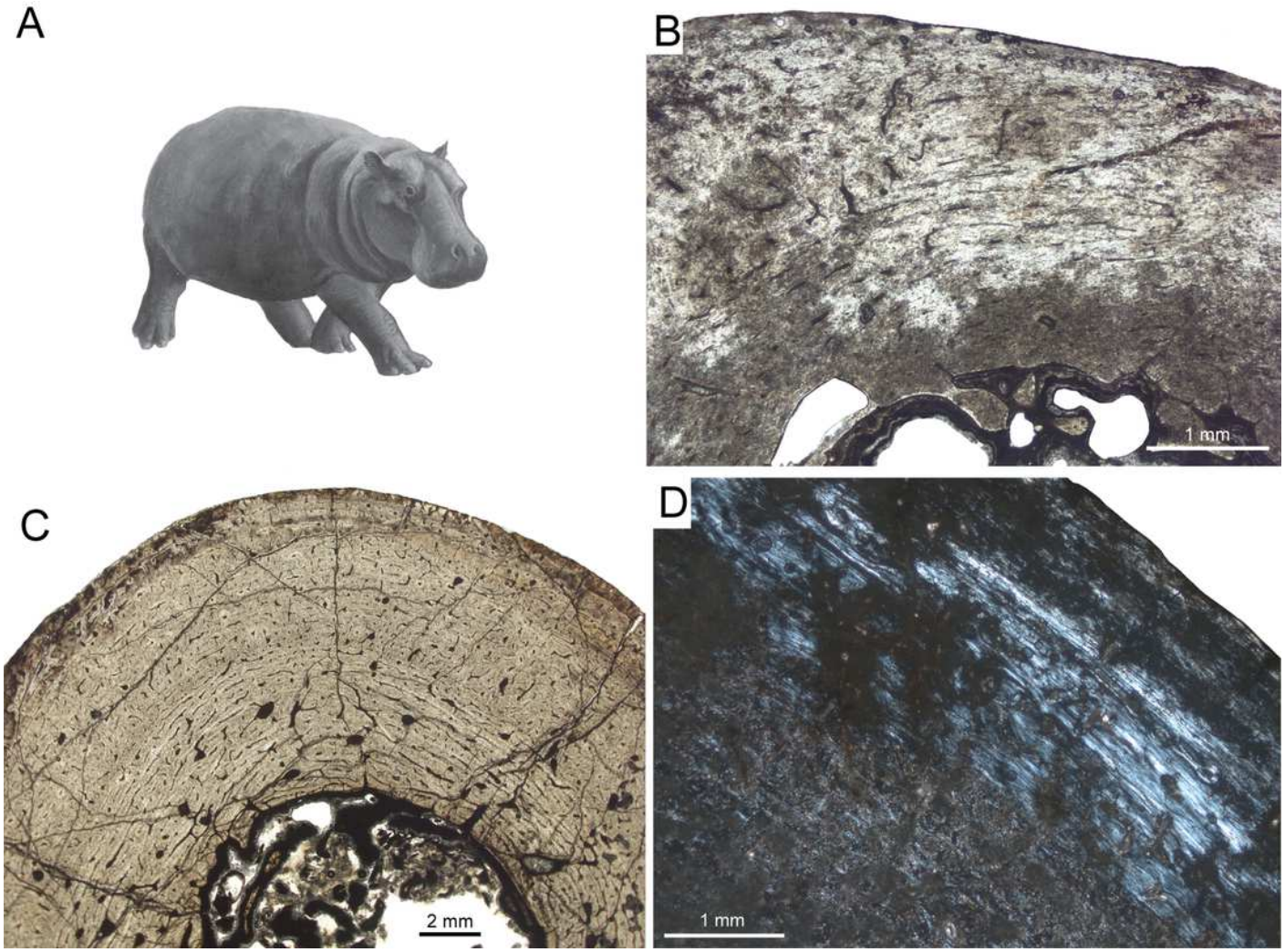

7

Figure 7: Histological features of *Sinomegaceros yabei*, the megacerine deer from the Pleistocene of Japan.

Histological images in linear polarised light of an adult femur (OMNH QV-4062) depicting A) the whole cross-section and B) a close-up of the outer cortex. The red bar in A) localizes the approximated position of the section on the life reconstruction (courtesy of Hirokazu Tokugawa), and the red rectangle indicates the area of the close-up. B) Note that seven LAGs are visible, as indicated by white arrows.

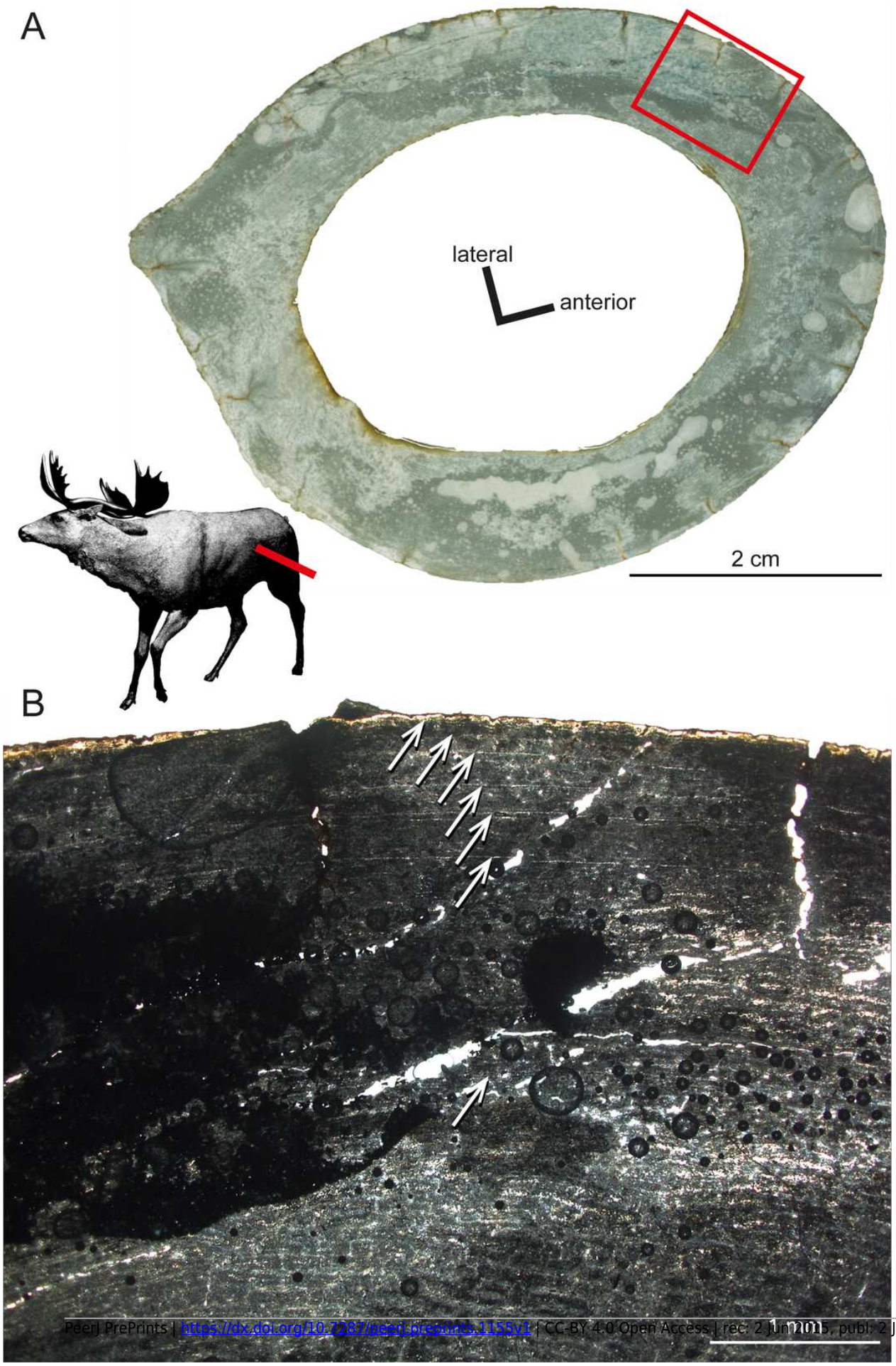

Figure 8: Bone histology of fossil island rodents.

Histological images A) and D) in linear polarised light, B) and E) in crossed polarised light, and C) and F) in crossed polarised light with additional use of lambda compensator. A-C) Adult *Mikrotia* sp. femur (specimen RGM.792085) showing disorganised, parallel-fibred/lamellar bone in its centre. D-F) Adult femur of *Leithia* sp. specimen NMB G 2160 displaying lamellar bone being pervaded by longitudinal to radial primary osteons and irregularly shaped and partially oblique secondary osteons.

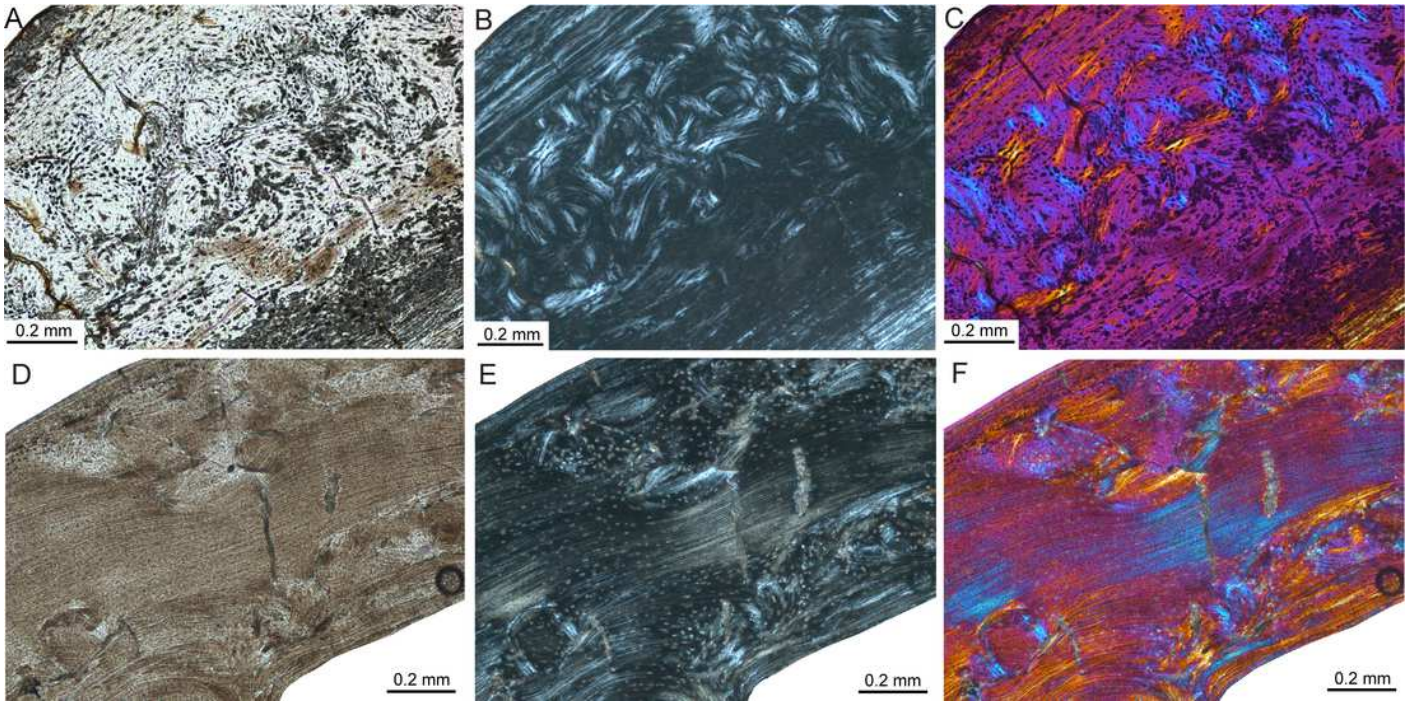

Figure 9: Bone histology of fossil ochotonids.

A) Life reconstruction of *Prolagus sardus* ("Prolagus3", courtesy of Wikimedia Commons - http://commons.wikimedia.org). Histological images B), D), F) in linear polarised light and C) and E) in crossed polarised light with additional use of lambda compensator. B, C) Lateral cortex of *Prolagus oeningensis* femur PIMUZ A/V 4532 showing subendosteal Haversian-like bone in the inner part and parallel-fibred bone in the central and outer part as well as three LAGs. D, E) Lateral cortex of *Prolagus imperialis* femur RGM.792094 displaying an identical pattern of bone tissue but five LAGs. F) Outer anterolateral cortex of *Prolagus sardus* femur NMB Ty.12659 displaying five LAGs. Note that the line in the lower third of the cortex is a resorption line (RL) and not a LAG. Occurrence of LAGs indicated by white or yellow arrows.



Table 2 (on next page)

Table 2: Summary of histological traits of major synapsid clades

(based on material sampled and references cited in the current study). The terminology follows Francillon-Vieillot et al. (1990).

Table 2: Summary of histological traits of major synapsid clades (based on material sampled and references cited in the current study). The terminology follows Francillon-Vieillot et al. (1990).

Histological traits	**Non-therapsid synapsids**	**Non-mammalian therapsids**	**Multitubercula-tes and early mammals**	**Monotremata**	**Euarchontogli-res**	**Laurasiatheria**	**Afrotheria**	**Xenarthra**
Main primary bone tissue types	fibrolamellar, parallel-fibred, lamellar	fibrolamellar	fibrolamellar, parallel-fibred, lamellar	fibrolamellar, lamellar	lamellar or parallel-fibred	fibrolamellar	fibrolamellar	fibrolamellar
Main vascularisation patterns	longitudinal, reticular, radial	plexiform, laminar, longitudinal, reticular, radial	longitudinal, radial, reticular	longitudinal, radial, reticular, circular	longitudinal, reticular, radial	longitudinal, reticular, radial, laminar, plexiform	circumferential, longitudinal, reticular, laminar, plexiform	longitudinal, reticular, radial
Lines of arrested growth	present	present	present	not documented	present	present	present	present
Remodelling	Haversian bone	Haversian bone	not documented	Haversian bone	Haversian bone; rodents: low content of Haversian systems	Haversian bone	Haversian bone	Haversian bone