

Comparison of incisional complications between skin closures using a simple continuous or intradermal pattern: a pilot study in horses undergoing ventral median celiotomy

Doreen Scharner¹, Claudia Gittel¹, Karsten Winter², Dominique Blaue³, Carola Schedlbauer³, Ingrid Vervuert³ and Walter Brehm¹

¹ Department for Horses, University of Leipzig, Leipzig, Germany

² Institute of Anatomy, Faculty of Medicine, University of Leipzig, Leipzig, Germany

³ Institute of Animal Nutrition, Nutrition Diseases and Dietetics, University of Leipzig, Leipzig, Germany

ABSTRACT

Background: Development of incisional complications following ventral median celiotomy might depend on suture pattern for skin closure.

Methods: In this prospective study, 21 healthy male horses underwent celiotomy. Skin closure was either performed via a continuous percutaneous pattern (CO group; 5 warmbloods/5 ponies) or an intradermal pattern (ID group; 5 warmbloods/6 ponies). Follow-up examination of the incisional site included daily monitoring for edema, dehiscence, and drainage. Transcutaneous ultrasound was performed at Days 3, 6, and 10 as well as on Week 8 and 12 to evaluate size of edema and presence or absence of sinus formation, and hernia formation. Prevalence of incisional infection on base of positive microbiological analysis at any time up to Day 10 was evaluated and compared between ID and CO group. Furthermore, edema size was analysed by a linear mixed-effect model for group and time dependency.

Results: Observed incisional complications included edema (9/10 in CO, 10/11 in ID), suture sinus formation (2/10 in CO, 1/11 in ID), surgical site infection (2/10 in CO, 0/11 in ID), and incisional hernia (1/10 in CO, 0/11 in ID). The overall prevalence of incisional infection was 9.5% without significant differences between both groups (20% in CO, 0% in ID; $p = 0.214$). Edema size was not dependent on time or group ($p = 0.545$ and $p = 0.627$, respectively).

Discussion: CO and ID suture pattern are appropriate for skin closure following ventral median celiotomy in horses. None of the animals in the continuous ID group developed surgical site infections, even without the use of antibiotics.

Subjects Veterinary Medicine, Surgery and Surgical Specialties

Keywords Exploratory laparotomy, Surgical site infection, Suture pattern, Complications, Incision

INTRODUCTION

Incisional complications, including edema, dehiscence, drainage or surgical site infection, and incisional hernia occur commonly following ventral midline celiotomy in horses,

Submitted 30 March 2018
Accepted 17 September 2018
Published 9 November 2018

Corresponding author
Doreen Scharner,
scharner@vetmed.uni-leipzig.de

Academic editor
Philip Kass

Additional Information and
Declarations can be found on
page 10

DOI 10.7717/peerj.5772

© Copyright
2018 Scharner et al.

Distributed under
Creative Commons CC-BY 4.0

OPEN ACCESS

leading to prolonged hospitalization, longer recovery times and increased cost (Kobluk *et al.*, 1989; French *et al.*, 2002; Mair & Smith, 2005). Despite ongoing research and advances in surgical technique over the last decade, rates cited for incisional complications still range from 16% to 62% (Lippold, 2001; Proudman *et al.*, 2002; Mair & Smith, 2005; Freeman *et al.*, 2012).

Many factors have been investigated for their influence on development of incisional complications, for example, breed, sex and pre-surgical condition of the horse (Colbath *et al.*, 2014; Darnaud *et al.*, 2016). However, they are fixed and can rarely be modified by the surgeon.

Several studies have focused on identifying risk factors associated with assorted suture materials and closure patterns. Factors that predispose to incisional complications include a near-far-far-near pattern (Kobluk *et al.*, 1989) and use of chromic catgut (Gibson *et al.*, 1989) for closure of linea alba. In one retrospective study, greater risk of incisional infection was evident with use of polyglactin-910 (vs. polydioxanone) suture (Honnas & Cohen, 1997). On the other hand, antibacterial coating of suture appears ineffective as a preventive measure in this setting (Bischofberger *et al.*, 2010). In another study, the risk of incisional infection was increased by stapling of skin incisions (Torfs *et al.*, 2010). Colbath *et al.* (2014) showed a reduction of incisional drainage with the use of a two-layer, modified subcuticular closure. However, until now, no clear consensus has emerged on a type of suture or a suturing pattern that is optimal to avoid complications in abdominal incisions (Salem, Proudman & Archer, 2016). Whether an intradermal, full-thickness continuous or an interrupted pattern is the best skin suture pattern to prevent surgical site infection in closure of ventral median celiotomy in horses is not apparent and further investigation is warranted (Torfs *et al.*, 2010).

The objective of this study was to compare incisional healing complications between skin closures using a simple continuous (CO) or intradermal (ID) pattern in horses undergoing celiotomy. Based on our clinical impression, we hypothesized, that ID suturing might lower the risk of incisional complications.

MATERIALS AND METHODS

This prospective study focusing on skin suture pattern was a spin-off of a larger project (approved by the local ethics committee, Landesdirektion Leipzig, TVV 32/15), in which 10 warmbloods and 11 ponies underwent celiotomy for harvest of abdominal fat and liver tissue. The animals were housed in individual straw-bedded boxes and were fed a hay diet. In advance, ponies and horses, evenly distributed, were selected at random for assignment of different skin suture pattern (simple continuous (CO) or intradermal (ID) group) by drawing lots.

All individuals were subjected to a lipopolysaccharide (LPS) challenge 15 h before surgery as part of the main project. For this purpose, LPS (10 ng/kg) from *Escherichia coli* 055:B5¹ was administered IV over 30 min. No analgesic was given prior to surgery.

In preparation for surgery, food but not water was withheld overnight. A standardized anesthesia protocol was used and consisted of IV 0.08 mg/kg romidifine and 0.03 mg/kg butorphanol for premedication, followed 10 min later by IV 0.08 mg/kg diazepam

¹ L6529, Lot Number 124M4D49V, Sigma-Aldrich Chemie GmbH, Munich, Germany.

Table 1 Detailed description of suture pattern and suture material.

Sutured tissue layer	Group	Suture pattern	Suture material	Brand name	Suture size (metric)
Peritoneum	CO, ID	Simple continuous	Polyglactin 910	Coated Vicryl TM rapide ^a	3.5
Linea alba	CO, ID	Simple continuous, bite-size at about 12 mm intervals	Lactomer 9-1 loop	Polysorb ^{TMb}	5
Subcutis	CO, ID	Simple continuous	Antibacterial polyglactin 910	Vicryl TM Plus ^c	4
Skin	CO	Simple continuous, percutaneous	Polyamide	Supramid ^d	4
	ID	Simple continuous, subcuticular	Antibacterial polyglactin 910	Vicryl TM Plus ^c	4

Notes:

Skin closure: CO, continuous percutaneous pattern; ID, intradermal pattern.

Manufacturer

^a Johnson & Johnson Medical GmbH, Ethicon Deutschland, Norderstedt, Germany.

^b Covidien Germany GmbH, Neustadt an der Donau, Germany.

^c Johnson & Johnson Medical GmbH, Ethicon Deutschland, Norderstedt, Germany.

^d B. Braun, Vet Care GmbH, Melsungen, Germany.

and 3 mg/kg ketamine for induction. For maintenance of anesthesia, animals were connected to a circle breathing circuit with isoflurane in oxygen. Additionally, lidocaine (0.05 mg/kg/min) was administered IV. No systemic or local antibiotics were applied pre-, intra- or post-surgery.

For surgery, horses were positioned in dorsal recumbency and the surgical site was prepared for aseptic surgery. At first, the prepuce was covered with dry gauze and closed with towel clamps. Afterwards, the ventral abdomen was clipped, and washed with antiseptic soap (Degraseptin®; Albrecht, Aulendorf, Germany), defatted with ethanol (PKH GmbH, Halle, Germany) and disinfected with iodine and 70% ethanol (Braunoderm®; B. Braun Medical AG, Melsungen, Germany). None of the animals had any evidence of previous abdominal surgery. One surgeon (WB) performed all surgical procedures. A 20 cm celiotomy (length determined via sterile ruler) was made in the pre-umbilical region on ventral skin midline by incision of skin, subcutis, and linea alba and a subsequent sharp dissection of ligamentum teres hepatis. In case of excessive gas accumulation in the large colon and cecum, decompression was performed via a suction unit using a 20-G hypodermic needle. To enable intraabdominal manipulation the abdominal cavity was irrigated with sterile lactated Ringer's solution (ponies, 500 ml; warmbloods, 1,000 ml). Retroperitoneal and mesocolic fat were harvested by dissection, and liver specimens were sampled via biopsy punch. In each instance, one to three g tissue was collected as part of the main study. In the event of serosal injuries, mesocolic suturing was performed at the discretion of the surgeon. Each abdominal incision was closed in four layers, whereby peritoneum, linea alba, and subcutis were closed equally in both groups (see Table 1). Skin closure was either performed via simple continuous (CO group) or via intradermal suture (ID group), with differences in suture pattern and suture material (see Table 1). Subsequent to wound closure a self-adhesive drape

(Fixomull[®] stretch; BSN Medical GmbH, Hamburg, Germany) was placed on the midline and secured with skin staples for incisional protection. In case of any loss of the drape during recovery, this was noticed.

Postsurgical treatment consisted of flunixin-meglumine with an initial dose of 1.1 mg/kg IV, followed by 0.6 mg/kg twice daily for 72 h (peroral). Following surgery, animals were subjected to physical examinations, routine blood work and pain evaluations during the intensive care period of 10 days. Self-adhesive drapes were replaced at 24 h after surgery and ultrasound of the ventral abdomen was performed for absence of increased peritoneal fluid. Wound protections were removed on Day 3. In the CO group, sutures were removed on Day 10 after disinfection of skin with iodine and 70% ethandol (Braunoderm[®]). Box rest was maintained for 12 weeks, thereafter horses were allowed to have access to a small paddock. Postoperative examinations of the abdominal incision were terminated on Week 12.

Progress of wound healing and incisional complications were assessed in a standardized manner by one surgeon (DS), who was aware of the respective skin suture.

Short-term follow-up (Day 1–Day 10) consisted of presence or absence (yes/no) of edema, dehiscence, and drainage at the incision site by clinical examination of the surgical site once daily. Any type of incisional drainage was defined as surgical site infection (Torfs *et al.*, 2010; Freeman *et al.*, 2012; Colbath *et al.*, 2014). Additionally, ultrasound of the surgical site was performed on Days 3, 6, and 10. To avoid contamination of the incision, the probe was covered with sterile surgical probes and sterile ultrasound gel was used (Sonogel[®]; Sonogel, Bad Camberg, Germany). Subcutaneous edema size immediately adjacent to the incision site was recorded at three locations (cranial, centre and caudal part of the incision). Post hoc, ultrasound images were measured and averaged for each time of investigation. For a transformation to a usual clinical evaluation to describe the incisional site in the results, size of edema was transferred to degree of edema (slight (edema size 5–15 mm), moderate (>15 but ≤25 mm), or severe (>25 mm)). Presence and absence of sinus formation (defined as any fluid-filled subcutaneous cavity) was also assessed by ultrasound.

Between Day 10 and Week 8 horses were evaluated daily by clinical examination and any swelling at the incisional region and discharge from the incision site was recorded. However, no further standardized examinations were performed in this time period.

At Week 8 and 12 wound healing was re-evaluated by a clinical examination and ultrasound of the incision site. At this time point, an additional focus on abdominal herniation as well as any deviation of the ventral abdominal wall (minimal distortions of the abdominal wall without palpable edges of a hernial ring) (Proudman, 2008) was undertaken.

Evidence of incisional infections was classified as yes in case of any positive microbiological culture in the drainage until Day 10. All other individuals were classified as no.

Statistical analysis relied on standard software². Data were checked for normality using the Shapiro–Wilk test. Categorical data for presence or absence of incisional infections was gathered in contingency tables and tested for dependency on suture pattern

² IBM SPSS Statistics, IBM Corporation; Armonk, NY.

via Fisher's exact test. Continuous data were calculated and expressed as mean \pm standard deviation, unless otherwise stated. Comparison of duration of anaesthesia between groups were analysed by Mann–Whitney U-test. Dependency of edema size on group (CO vs. ID) or time was investigated by a linear mixed-effect model.

Level of significance for two-tailed tests was set at $p < 0.05$.

RESULTS

A total of 21 healthy geldings (5 warmbloods/5 ponies in group CO; 5 warmbloods/6 ponies in group ID) were included in this study. Overall mean age was 10.2 years (range, 5–13 years) in warmbloods and 8.4 years (range, 4–14 years) in ponies. Mean body weight was 592 kg (range, 477–665 kg) in warmbloods. In ponies, mean BW was 115 kg (83–186 kg).

In all animals coeliotomy was successfully completed and horses recovered without complications. Surgical time for celiotomy (time from incision to skin suture) did not differ between both groups, with a median value (\pm interquartile range) of 60 (± 12.5) minutes in the CO group and 57.5 (± 17.5) minutes in the ID group ($p = 0.776$). Excess gas in large colon and cecum had to be removed in two ponies (horses 1 and 7). In seven animals (horses 1, 3, 5, 7, 14, 20, and 21) mesocolic suturing was performed. None of the horses, which were mentioned above with any additional intra operative manipulations, developed incisional infection. During recovery, a self-adhesive drape dislodged in one animal (horse 20); the wound was disinfected and the drape was replaced. This horse did not experience an incisional infection.

Observed incisional complications are summarized in [Table 2](#). Dehiscence did not occur.

Overall prevalence of incisional infection was 9.5%. With regard to suture pattern, incidence of surgical site infection was 20% and 0% in the CO and the ID group, respectively. However, this difference was not significant ($p = 0.214$).

Drainage, serosanguinous initially and later purulent, was documented in two warmbloods (horses 6 and 10, both in group CO). Each drainage was subsequently confirmed as incisional infections by microbiologic analysis of wound drainage (*Streptococcus equi* ssp. *zooepidemicus* in horse 6, *Streptococcus dysgalactiae* in horse 10), with both bacterial isolates being resistant to penicillin and gentamicin. Treatment in these cases consisted of intense physical massage with hydrotherapy. No local antibiotics were administered. Drainage persisted for 1 week and resolved without further treatment.

Edema developed in all animals, with exception of two ponies (horses 9 and 17), occurring most frequently between Days 3 and 6 and peaking at Day 6. Values of edema size are presented in [Fig. 1](#). Edema size was not dependent on time or group ($p = 0.545$ and $p = 0.627$, respectively).

Ultrasound confirmed sinus formation in three horses (2 warmbloods in group CO, 1 warmblood in group ID). Two of them developed the incisional drainage (horse 6 and horse 10, infection as proved by bacterial colonization; see above). In the horse from the ID group (horse 8), sinus formation resolved by Day 10, without any occurrence of incision site drainage.

Table 2 Breed, suture pattern, and incisional complications in each horse.

Horse no.	Breed	Suture pattern	Degree of edema on Day 6	Sinus formation (Day)	Surgical site infection (Day)	Hernia
1	P	CO	Severe	No	No	No
2	W	ID	Moderate	No	No	No
3	P	ID	Severe	No	No	No
4	W	ID	Slight	No	No	No
5	P	ID	Slight	No	No	No
6	W	CO	Severe	Yes (10)	Yes (4–12)	No
7	P	CO	Slight	No	No	No
8	W	ID	Severe	Yes (3 and 6)	No	No
9	P	ID	None	No	No	No
10	W	CO	Moderate	Yes (3 and 6)	Yes (6–12)	Yes
11	P	ID	Slight	No	No	No
12	W	CO	Moderate	No	No	No
13	P	CO	Slight	No	No	No
14	W	CO	Moderate	No	No	No
15	P	ID	Moderate	No	No	No
16	W	ID	Moderate	No	No	No
17	P	CO	None	No	No	No
18	P	CO	Slight	No	No	No
19	W	ID	Moderate	No	No	No
20	P	ID	Moderate	No	No	No
21	W	CO	Moderate	No	No	No

Note:

P, pony; W, warmblood; CO, continuous percutaneous pattern; ID, intradermal pattern; degree of edema: slight (5–15 mm); moderate (>15 but ≤25 mm); severe (>25 mm).

Only one horse showed incisional herniation in Week 12. This horse suffered from incisional drainage previously. The hernia created a minimal distortion of the abdominal wall profile.

DISCUSSION

The purpose of this pilot study was to determine whether ID skin sutures could minimize the risk of incisional complications following ventral midline celiotomy in horses.

None of the horses subjected to ID suturing exhibited any signs of wound infection, which was not the case with closures by CO pattern. This effect might be of clinical importance, however, in this study it failed to have statistical significance.

A major advantage of this prospective randomized non-blinded experimental study is its use of a standardized protocol with regard to surgical technique (performed by a single surgeon), postoperative care and postoperative follow-up examinations by the same individual. Furthermore, the 12-week follow-up duration also enabled observation of late incisional complications, which has not been performed in such a setting before.

Intra- and postoperative management was standardized. In all cases, the incision was covered with self-adhesive drapes secured by skin staples for protection of the wound.

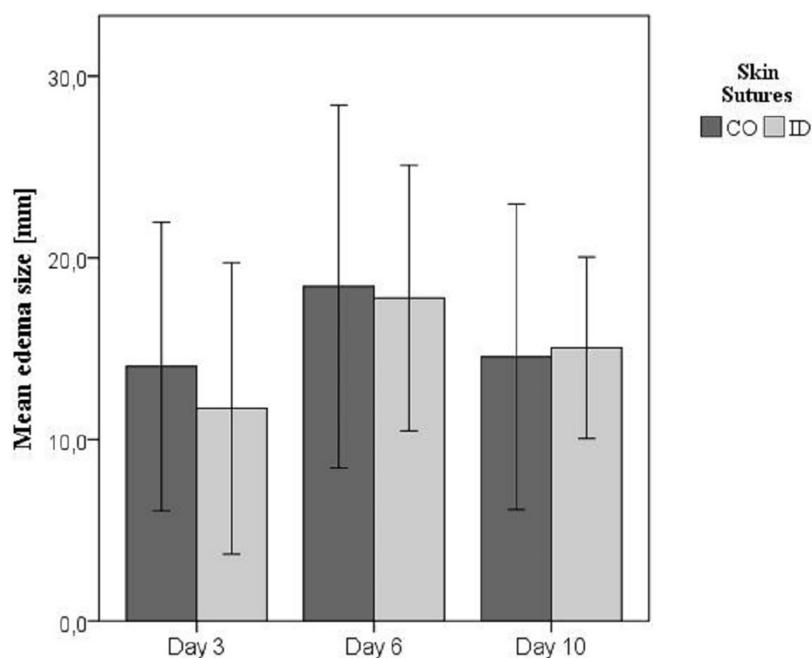


Figure 1 Mean edema size in millimeter (\pm standard deviation) on Days 3, 6, and 10. Edema size measured by transcutaneous ultrasound on Days 3, 6, and 10. Skin sutures: CO, continuous percutaneous pattern; ID, intradermal pattern. [Full-size !\[\]\(fd7fe780e8fd8eece60268c87d0c3e04_img.jpg\) DOI: 10.7717/peerj.5772/fig-1](https://doi.org/10.7717/peerj.5772/fig-1)

Contamination during recovery is a common source of postoperative infection (*Ingle-Fehr et al., 1997; Klohnen, 2009*). By potentially exposing such horses to more incisional contamination than otherwise is encountered, poor quality of anaesthetic recovery bears an association with incisional infection (*Freeman et al., 2012*). Protective bandages may be used to lower rates of incisional infection (*Smith et al., 2007; Tnibar et al., 2013*), although this strategy confers no postoperative benefit according to *Torfs et al. (2010)*. In our opinion, however, protecting the wound from contamination during recovery and early postoperative recuperation is of major importance. Self-adhesive drapes secured by skin staples were used as wound protection in our animals. The relation between quality of recovery and occurrence of surgical site infection was not investigated in this study.

In the current study, no perioperative antibiotics were given, due to the fact that use of antimicrobials in clean surgeries is controversial in both human and veterinary medicine and probably not necessary (*Barie & Eachempati, 2005; Santschi, 2006*). However, puncture of the large intestine needs to be classified as ‘clean-contaminated’ and, thereby, maybe necessitating a prophylactic use of antibiotics for 3 days, as it is common in clinical colic cases (*Traub-Dargatz et al., 2002; Durward-Akhurst et al., 2013; Isgren et al., 2017*). However, none of the ponies with gas removal from the intestine, developed surgical site infection. In the two horses, which suffered from abdominal wound infections, none of the antibiotics, which are routinely administered without any resistogram (penicillin and gentamicin) (*Traub-Dargatz et al., 2002; Isgren et al., 2017*), would have been effective in these cases. Consequently, antibiotic use should be well-considered and

held to an absolute minimum depending on type of surgery and condition of the horses. In equine colic surgery, reduction of antibiotics to perioperative use only may be a reasonable approach.

Limitation of this pilot study is the design as a spin-off study on a homogenous cohort and, therefore, animal numbers, breed, and sex were determined by the global project. To avoid a bias by improved wound healing in ponies (*Wilmink & Van Weeren, 2005*), ponies and horses were equally distributed in ID or CO group.

The small sample size in combination with analysis of categorical data (yes/no) have mainly contributed to a type II error and, therefore, this study failed to give any statistical significance. A post hoc power analysis for a reduction of incisional infection in one group by 20%, revealed that per group 45 horses would have been necessary to obtain significant differences between both groups. Therefore, larger studies with inclusion of equine patients are warranted to confirm statistically significant differences in skin suture pattern.

Another limitation of this study was the inability to blind the postoperative investigator due to the obvious existence of skin sutures. However, examinations of the incision site were categorized qualitatively (yes/no) or quantitatively in case of edema size. Therefore, biased results were reduced.

In this study, closure of the laparotomy wounds involved four layers: peritoneum, linea alba, subcutis, and skin. While many surgeons may omit peritoneal closure, this step is critical in our opinion, helping to minimize problems in wound healing. In doing so, efflux of peritoneal fluid or sterile washings (used to flush the abdominal cavity during surgery) into the wound and subcutaneous swelling are prevented. To avoid any risk of peritoneal rupture while suturing, peritoneum, and linea alba may be closed in a fractional way. However, even the latest editions of textbooks on equine surgery still suggest that suturing the peritoneum encourages the formation of abdominal adhesions (*Freeman, 2008*). This is in reference to a publication by *Swanwick & Milne (1973)* examining the aggressive use peritoneal sutures under experimental conditions. Although peritoneal adhesions occurred at a 50% rate with use of polyester suture, the corresponding rate for unsutured peritoneum was 27.2%. It is our contention that these conclusions warrant a closer look. In another study, *Huskamp* also maintains that suturing of the peritoneum is an essential step in the closure of laparotomy wounds (*Huskamp, 1982*). This opinion is supported by studies comparing rates of infected incisions after laparotomy for colic surgery in horses, in which a significant reduction in wound healing complications were detected when peritoneal suturing was performed compared to unsutured peritoneum (*Torfs et al., 2010; Scharner et al., 2017*).

In the current study, subcutaneous suturing was performed, as this has shown to reduce the likelihood of developing incisional complications (*Smith et al., 2007*). This is in accordance with Halsted's principles, particularly the need to avoid dead space. Moreover, the time or effort saved by abandoning subcutaneous closure, when using a two-layer closure technique, is negligible, relative to total operative duration. For subcutaneous suturing, we used VicrylTM Plus, an antibacterial-coated suture proven to prevent in vitro and in vivo colonization by *Staphylococcus aureus*, multiresistant *Staphylococcus aureus*,

Staphylococcus epidermidis, and *E. coli*, thus potentially reducing surgical site infections (Rothenburger et al., 2002; Storch, Rothenburger & Jacinto, 2004; Edmiston et al., 2006; Marco et al., 2007). Still, the efficacy of such material is subject to debate, having failed to reduce the likelihood of incisional complications in the current study and in another study (Bischofberger et al., 2010).

Skin closure traditionally is achieved by non-absorbable suture in continuous or interrupted pattern. This method is represented by the CO group. Conceptually, the apposition of skin edges (and therefore sealing of the wound) attained by suturing is superior to that of stapling. This might be an explanation for increased risk of incisional infection when using staples for skin closure (Torfs et al., 2010). In humans, ID suturing is often selected for aesthetic reasons, but also yielding good results in terms of incisional infection (Johnson, Young & Reilly, 2006), potentially due to tightness of wound edges, and avoidance of a percutaneous suture canal. A similar finding in horses were published by Colbath et al. (2014), in which a significantly reduced incidence of incisional drainage was found in accordance with a subcuticular closure compared to a percutaneous skin closure. Similarly, in the present study none of the horses subjected to cutaneous ID suturing exhibited any signs of wound infection. However, the present study failed to show any significant difference between groups with regard to surgical site infection. When comparing ID and CO suturing, it should be taken into account, that in both groups different suture materials have been used for skin closure (see Table 1) and might have influenced this result.

Incisional edema was the most frequent finding in wound healing in our study horses. This is in accordance with other studies, reporting a prevalence of edema of 70–90% (Santschi, 2006; Smith et al., 2007; Bischofberger et al., 2010; Anderson, Bracamonte & Hendrick, 2014), which is not regarded as a postoperative complication in many studies. However, if severe and persistent, an abnormal healing of the incision is likely (Gibson et al., 1989). Furthermore, some studies show a strong correlation between severe wound edema and subsequent surgical site infection (Coomer et al., 2007; Scharner et al., 2017). This was not shown in the present cohort, possibly related to the lack of sufficient power of the study.

The definition of incisional infection, suppuration and drainage varies greatly in different studies, making comparisons difficult. By some authors, any drainage is indicative of infection (Ingle-Fehr et al., 1997; Torfs et al., 2010; Freeman et al., 2012). Other studies differentiate between drainage and infection (Smith et al., 2007; Colbath et al., 2014; Darnaud et al., 2016; Isgren et al., 2017) and partially consider serosanguinous wound discharge as a normal accompaniment of recovery from anaesthesia. However, we consider this as a lack of tight abdominal wound closure, not seen in our population of animals.

Dehiscence did not occur in our research horses. Although the reported incidence is low (1.1–9%), incisional dehiscence of the equine abdomen is a catastrophic and potentially fatal event, especially if linea alba is involved (Kobluk et al., 1989; Smith et al., 2007; Bischofberger et al., 2010; Anderson, Bracamonte & Hendrick, 2014; Anderson et al., 2015).

Sinus formation was diagnosed via ultrasound. The latter is essential for detecting this condition (Wilson et al., 1989; Trostle & Hendrickson, 1995; Chism et al., 2000;

Lippold, 2001). In our animal population, sinuses developed in three horses (14.3%); but progression to incisional infection occurred in only two of them. In contrast, *Wilson et al. (1989)* observed a proportionately high rate (71.4%) of sinus formation in their study group.

Incisional hernia did occur in one of the horses we studied (4.8%). This occurred following a previous incisional infection. Published incisional hernia rates range from 3.2% to 17% (*Gibson et al., 1989; Kobluk et al., 1989; Phillips & Walmsley, 1993; Wilson, Baker & Boero, 1995; Honnas & Cohen, 1997; Anderson et al., 2015*), which is in accordance with our findings. Overall, our observed prevalence of incisional infection was low (9.5%), based on healthy horses in an experimental setting. However, haemodynamic conditions might be altered by LPS-infusion prior surgery leading to systemically compromised individuals, similarly to colic horses. Despite a lack of abnormalities in the clinical evaluation prior to anaesthesia in the study horses, the alterations of haematocrit, platelet function, white blood cells and cardiac output by LPS-infusion was not investigated in this part of the study. Therefore, abnormalities could have been present 15 h after LPS-administration, as shown in a study in foals with experimental endotoxemia (*Wong et al., 2013*). Moreover, it should be taken into account that no analgesic has been administered after the LPS-challenge before surgery in our study. With regard to the intestinal handling and tissue sampling that were done, with some intra-abdominal bleeding, manipulations were comparable to relatively simple colic surgery (without enterotomy or resection). Moreover, it has been shown, that opening of the bowel did not influence occurrence of incisional infection (*Gibson et al., 1989; Kobluk et al., 1989; Phillips & Walmsley, 1993; Wilson, Baker & Boero, 1995; Coomer et al., 2007; Bischofberger et al., 2010*).

It is worth mentioning that none of the ponies developed an incisional infection. This might be an effect of reduced body weight (*Wilson, Baker & Boero, 1995; Darnaud et al., 2016*) or a breed specificity, which is associated with better wound healing (*Wilmink & Van Weeren, 2005*). However, due to the small sample size and the low incidence of surgical site infection, a comparison between ponies and horses was not possible.

CONCLUSION

In conclusion, both CO and ID suture patterns are applicable for skin closure following ventral median celiotomy in horses. None of the animals in the continuous ID group developed surgical site infections, even without use of antibiotics. However, further studies are necessary to prove this beneficial effect in clinical cases.

ADDITIONAL INFORMATION AND DECLARATIONS

Funding

The study was funded by the German Research Foundation (Deutsche Forschungsgemeinschaft [DFG], project number: VE 225/9-1) and was also supported by the University of Leipzig. We received support from the German Research Foundation (DFG)

and Leipzig University within the program of Open Access Publishing. There was no additional external funding received for this study. The funders had no role in study design, data collection and analysis, decision to publish, or preparation of the manuscript.

Grant Disclosures

The following grant information was disclosed by the authors:

German Research Foundation (Deutsche Forschungsgemeinschaft [DFG], project number: VE 225/9-1).

University of Leipzig.

German Research Foundation (DFG) and Leipzig University within the program of Open Access Publishing.

Competing Interests

The authors declare that they have no competing interests.

Author Contributions

- Doreen Scharner conceived and designed the experiments, performed the experiments, analyzed the data, prepared figures and/or tables, authored or reviewed drafts of the paper, approved the final draft.
- Claudia Gittel conceived and designed the experiments, performed the experiments, analyzed the data, prepared figures and/or tables, authored or reviewed drafts of the paper, approved the final draft.
- Karsten Winter analyzed the data, contributed reagents/materials/analysis tools, prepared figures and/or tables, authored or reviewed drafts of the paper.
- Dominique Blaue performed the experiments, contributed reagents/materials/analysis tools, authored or reviewed drafts of the paper.
- Carola Schedlbauer performed the experiments, contributed reagents/materials/analysis tools, authored or reviewed drafts of the paper.
- Ingrid Vervuert contributed reagents/materials/analysis tools, authored or reviewed drafts of the paper.
- Walter Brehm conceived and designed the experiments, performed the experiments.

Ethics

The following information was supplied relating to ethical approvals (i.e. approving body and any reference numbers):

The study was approved by the local ethics committee, Landesdirektion Leipzig, Germany (TVV 32/15).

Data Availability

The following information was supplied regarding data availability:

The raw data are included in a [Supplemental File](#).

Supplemental Information

Supplemental information for this article can be found online at <http://dx.doi.org/10.7717/peerj.5772#supplemental-information>.

REFERENCES

- Anderson SL, Bracamonte JL, Hendrick S. 2014.** Ex vivo evaluation of 7 polydioxanone for closure of equine ventral midline celiotomies. *Canadian Journal of Veterinary Research* **78(2)**:156–160.
- Anderson SL, Devick I, Bracamonte JL, Hendrick S, Barber SM, Carmalt JL, Wilson DG. 2015.** Occurrence of incisional complications after closure of equine celiotomies with USP 7 polydioxanone. *Veterinary Surgery* **44(4)**:521–526
DOI [10.1111/j.1532-950x.2014.12275.x](https://doi.org/10.1111/j.1532-950x.2014.12275.x).
- Barie PS, Eachempati SR. 2005.** Surgical site infections. *Surgical clinics of North America* **85(6)**:1115–1135 DOI [10.1016/j.suc.2005.09.006](https://doi.org/10.1016/j.suc.2005.09.006).
- Bischofberger AS, Brauer T, Gugelchuk G, Klohnen A. 2010.** Difference in incisional complications following exploratory celiotomies using antibacterial-coated suture material for subcutaneous closure: prospective randomised study in 100 horses. *Equine Veterinary Journal* **42(4)**:304–309 DOI [10.1111/j.2042-3306.2009.00020.x](https://doi.org/10.1111/j.2042-3306.2009.00020.x).
- Chism PN, Latimer FG, Patton CS, Rohrbach BW, Blackford JT. 2000.** Tissue strength and wound morphology of the equine linea alba after ventral median celiotomy. *Veterinary Surgery* **29(2)**:145–151 DOI [10.1111/j.1532-950x.2000.00145.x](https://doi.org/10.1111/j.1532-950x.2000.00145.x).
- Colbath AC, Patipa L, Berghaus RD, Parks AH. 2014.** The influence of suture pattern on the incidence of incisional drainage following exploratory laparotomy. *Equine Veterinary Journal* **46(2)**:156–160 DOI [10.1111/evj.12091](https://doi.org/10.1111/evj.12091).
- Coomer RPC, Mair TS, Edwards GB, Proudman CJ. 2007.** Do subcutaneous sutures increase risk of laparotomy wound suppuration? *Equine Veterinary Journal* **39(5)**:396–399
DOI [10.2746/042516407x195123](https://doi.org/10.2746/042516407x195123).
- Darnaud SJM, Southwood LL, Aceto HW, Stefanovski D, Tomassone L, Zarucco L. 2016.** Are horse age and incision length associated with surgical site infection following equine colic surgery? *Veterinary Journal* **217**:3–7 DOI [10.1016/j.tvjl.2016.09.004](https://doi.org/10.1016/j.tvjl.2016.09.004).
- Durward-Akhurst SA, Mair TS, Boston R, Dunkel B. 2013.** Comparison of two antimicrobial regimens on the prevalence of incisional infections after colic surgery. *Veterinary Record* **172(11)**:287 DOI [10.1136/vr.101186](https://doi.org/10.1136/vr.101186).
- Edmiston CE, Seabrook GR, Goheen MP, Krepel CJ, Johnson CP, Lewis BD, Brown KR, Towne JB. 2006.** Bacterial adherence to surgical sutures: can antibacterial-coated sutures reduce the risk of microbial contamination? *Journal of the American College of Surgeons* **203(4)**:481–489 DOI [10.1016/j.jamcollsurg.2006.06.026](https://doi.org/10.1016/j.jamcollsurg.2006.06.026).
- Freeman DE. 2008.** Abdominal closure. In: White NA, Moore JN, Mair TS, eds. *The Equine Acute Abdomen*. Jackson: Teton NewMedia, 539–550.
- Freeman KD, Southwood LL, Lane J, Lindborg S, Aceto HW. 2012.** Post operative infection, pyrexia and perioperative antimicrobial drug use in surgical colic patients. *Equine Veterinary Journal* **44(4)**:476–481 DOI [10.1111/j.2042-3306.2011.00515.x](https://doi.org/10.1111/j.2042-3306.2011.00515.x).
- French NP, Smith J, Edwards GB, Proudman CJ. 2002.** Equine surgical colic: risk factors for postoperative complications. *Equine Veterinary Journal* **34(5)**:444–449
DOI [10.2746/042516402776117791](https://doi.org/10.2746/042516402776117791).
- Gibson KT, Curtis CR, Turner AS, McIlwraith CW, Aanes WA, Stashak TS. 1989.** Incisional hernias in the horse. Incidence and predisposing factors. *Veterinary Surgery* **18(5)**:360–366
DOI [10.1111/j.1532-950x.1989.tb01100.x](https://doi.org/10.1111/j.1532-950x.1989.tb01100.x).
- Honnas CM, Cohen ND. 1997.** Risk factors for wound infection following celiotomy in horses. *Journal of the American Veterinary Medical Association* **210(1)**:78–81.

- Huskamp B. 1982.** Diagnosis and treatment of acute abdominal conditions in the horse; various types and frequency as seen at the animal hospital in Hochmoor. In: *Proceedings of the 1st Equine Colic Research Symposium, Athens, Georgia*, 261–272.
- Ingle-Fehr JE, Baxter GM, Howard RD, Trotter GW, Stashak TS. 1997.** Bacterial culturing of ventral median celiotomies for prediction of postoperative incisional complications in horses. *Veterinary Surgery* **26**(1):7–13 DOI [10.1111/j.1532-950x.1997.tb01456.x](https://doi.org/10.1111/j.1532-950x.1997.tb01456.x).
- Isgren CM, Salem SE, Archer DC, Worsman FCF, Townsend NB. 2017.** Risk factors for surgical site infection following laparotomy: effect of season and perioperative variables and reporting of bacterial isolates in 287 horses. *Equine Veterinary Journal* **49**(1):39–44 DOI [10.1111/evj.12564](https://doi.org/10.1111/evj.12564).
- Johnson A, Young D, Reilly J. 2006.** Caesarean section surgical site infection surveillance. *Journal of Hospital Infection* **64**(1):30–35 DOI [10.1016/j.jhin.2006.03.020](https://doi.org/10.1016/j.jhin.2006.03.020).
- Klohn A. 2009.** New perspectives in postoperative complications after abdominal surgery. *Veterinary Clinics of North America: Equine Practice* **25**(2):341–350 DOI [10.1016/j.cveq.2009.05.003](https://doi.org/10.1016/j.cveq.2009.05.003).
- Kobluk CN, Ducharme NG, Lumsden JH, Pascoe PJ, Livesey MA, Hurtig M, Horney FD, Arighi M. 1989.** Factors affecting incisional complication rates associated with colic surgery in horses: 78 cases (1983–1985). *Journal of the American Veterinary Medical Association* **195**(5):639–642.
- Lippold BS. 2001.** Incisional complications following median laparotomy in horses. Doctoral thesis. University of Bern.
- Mair TS, Smith LJ. 2005.** Survival and complication rates in 300 horses undergoing surgical treatment of colic. Part 2: short-term complications. *Equine Veterinary Journal* **37**(4):303–309 DOI [10.2746/0425164054529364](https://doi.org/10.2746/0425164054529364).
- Marco F, Vallez R, Gonzalez P, Ortega L, De La Lama J, Lopez-Duran L. 2007.** Study of the efficacy of coated Vicryl plus® antibacterial suture in an animal model of orthopedic surgery. *Surgical Infections* **8**(3):359–366 DOI [10.1089/sur.2006.013](https://doi.org/10.1089/sur.2006.013).
- Phillips TJ, Walmsley JP. 1993.** Retrospective analysis of the results of 151 exploratory laparotomies in horses with gastrointestinal disease. *Equine Veterinary Journal* **25**(5):427–431 DOI [10.1111/j.2042-3306.1993.tb02985.x](https://doi.org/10.1111/j.2042-3306.1993.tb02985.x).
- Proudman CJ. 2008.** Postoperative complications. In: White NA, Moore JN, Mair TS, eds. *The Equine Acute Abdomen*. Jackson: Teton NewMedia, 564–577.
- Proudman CJ, Smith JE, Edwards GB, French NP. 2002.** Long-term survival of equine surgical colic cases. Part 1: patterns of mortality and morbidity. *Equine Veterinary Journal* **34**(5):432–437 DOI [10.2746/042516402776117845](https://doi.org/10.2746/042516402776117845).
- Rothenburger S, Spangler D, Bhende S, Burkley D. 2002.** In vitro antimicrobial evaluation of Coated VICRYL* Plus Antibacterial Suture (coated polyglactin 910 with triclosan) using zone of inhibition assays. *Surgical Infections* **3**(3 Suppl 1):S79–S87 DOI [10.1089/10962960260496361](https://doi.org/10.1089/10962960260496361).
- Salem SE, Proudman CJ, Archer DC. 2016.** Prevention of post operative complications following surgical treatment of equine colic: current evidence. *Equine Veterinary Journal* **48**(2):143–151 DOI [10.1111/evj.12517](https://doi.org/10.1111/evj.12517).
- Santschi EM. 2006.** Prevention of postoperative infections in horses. *Veterinary Clinics of North America: Equine Practice* **22**(2):323–334 DOI [10.1016/j.cveq.2006.03.002](https://doi.org/10.1016/j.cveq.2006.03.002).
- Scharner D, Winter K, Brehm W, Kämpfert M, Gittel C. 2017.** Incisional complications following ventral median coeliotomy in horses does suturing of the peritoneum reduce the risk? *Tierärztliche Praxis: Ausgabe G, Grosstiere/Nutztiere* **45**(1):24–32.

- Smith LJ, Mellor DJ, Marr CM, Reid SWJ, Mair TS. 2007.** Incisional complications following exploratory celiotomy: does an abdominal bandage reduce the risk? *Equine Veterinary Journal* **39**(3):277–283 DOI [10.2746/042516407x193963](https://doi.org/10.2746/042516407x193963).
- Storch ML, Rothenburger SJ, Jacinto G. 2004.** Experimental efficacy study of coated VICRYL plus antibacterial suture in guinea pigs challenged with *Staphylococcus aureus*. *Surgical Infections* **5**(3):281–288 DOI [10.1089/sur.2004.5.281](https://doi.org/10.1089/sur.2004.5.281).
- Swanwick RA, Milne FJ. 1973.** The non-suturing of parietal peritoneum in abdominal surgery of the horse. *Veterinary Record* **93**(12):328–335 DOI [10.1136/vr.93.12.328](https://doi.org/10.1136/vr.93.12.328).
- Tnibar A, Grubbe Lin K, Thurøe Nielsen K, Christophersen MT, Lindegaard C, Martinussen T, Ekstrøm CT. 2013.** Effect of a stent bandage on the likelihood of incisional infection following exploratory coeliotomy for colic in horses: a comparative retrospective study. *Equine Veterinary Journal* **45**(5):564–569 DOI [10.1111/evj.12026](https://doi.org/10.1111/evj.12026).
- Torfs S, Levet T, Delesalle C, Dewulf J, Vlamincx L, Pille F, Lefere L, Martens A. 2010.** Risk factors for incisional complications after exploratory celiotomy in horses: do skin staples increase the risk? *Veterinary Surgery* **39**(5):616–620 DOI [10.1111/j.1532-950x.2009.00636.x](https://doi.org/10.1111/j.1532-950x.2009.00636.x).
- Traub-Dargatz JL, George JL, Dargatz DA, Morley PS, Southwood LL, Tillotson K. 2002.** Survey of complications and antimicrobial use in equine patients at veterinary teaching hospitals that underwent surgery because of colic. *Journal of the American Veterinary Medical Association* **220**(9):1359–1365 DOI [10.2460/javma.2002.220.1359](https://doi.org/10.2460/javma.2002.220.1359).
- Trostle SS, Hendrickson DA. 1995.** Suture sinus formation following closure of ventral midline incisions with polypropylene in three horses. *Journal of the American Veterinary Medical Association* **207**(6):742–745.
- Wilmink JM, Van Weeren PR. 2005.** Second-intention repair in the horse and pony and management of exuberant granulation tissue. *Veterinary Clinics of North America: Equine Practice* **21**(1):15–32 DOI [10.1016/j.cveq.2004.11.014](https://doi.org/10.1016/j.cveq.2004.11.014).
- Wilson DA, Badertscher RR, Boero MJ, Baker GJ, Foreman JH. 1989.** Ultrasonographic evaluation of the healing of ventral midline abdominal incisions in the horse. *Equine Veterinary Journal* **21**(S7):107–110 DOI [10.1111/j.2042-3306.1989.tb05667.x](https://doi.org/10.1111/j.2042-3306.1989.tb05667.x).
- Wilson DA, Baker GJ, Boero MJ. 1995.** Complications of celiotomy incisions in horses. *Veterinary Surgery* **24**(6):506–514 DOI [10.1111/j.1532-950x.1995.tb01362.x](https://doi.org/10.1111/j.1532-950x.1995.tb01362.x).
- Wong DM, Sponseller BA, Alcott CJ, Agbedanu PN, Wang C, Hsu WH. 2013.** Effects of intravenous administration of polymyxin B in neonatal foals with experimental endotoxemia. *Journal of the American Veterinary Medical Association* **243**(6):874–881 DOI [10.2460/javma.243.6.874](https://doi.org/10.2460/javma.243.6.874).